BMC Neurology

CASE REPORT Open Access

A rare presentation of pediatric MOG-antibody-associated neuroretinitis: a case report

Ayfer Arduç-Akçay[1*], Yusuf Hüseyin Berrak[2] and Ayşe Yıldız-Taş[3]

Abstract

Background Neuroretinitis (NR) is an uncommon inflammatory optic neuropathy characterized by optic disc edema and macular exudates. Although NR may arise from infectious or idiopathic causes, its association with myelin oligodendrocyte glycoprotein antibody-associated disease (MOGAD) is exceptionally rare in children. Early recognition is critical, as MOGAD-related ocular involvement can respond favorably to prompt immunotherapy.

Case presentation We report an 11-year-old girl presenting with acute, painless visual loss in the right eye following one week of ocular pain with eye movements. Ophthalmologic evaluation revealed marked optic disc edema, splinter hemorrhages, and early macular exudation. MRI demonstrated right optic nerve thickening with T2-FLAIR hyperintensity, and optical coherence tomography showed subretinal fluid extending to the fovea. Extensive infectious testing was negative. Serum MOG-IgG was positive, supporting a diagnosis of MOGAD-associated NR. The patient received high-dose intravenous corticosteroids followed by intravenous immunoglobulin (IVIG), resulting in rapid visual improvement. A partial macular star developed during the early recovery phase. Maintenance therapy with mycophenolate mofetil was initiated due to IVIG intolerance and continued for 24 months. Over a 3-year follow-up period, the patient experienced full visual recovery without clinical relapses, although residual optic nerve thinning was observed on MRI.

Conclusion This case highlights a rare pediatric presentation of MOGAD manifesting as NR and underscores the importance of considering MOG-IgG testing in children presenting with optic disc edema and macular exudation. Early and sustained immunotherapy can lead to complete visual recovery and may reduce the risk of recurrent demyelinating episodes.

Keywords Myelin oligodendrocyte glycoprotein antibody-associated disease (MOGAD), Neuroretinitis, Pediatric demyelinating disease, Optic disc edema, Macular star, Visual loss, Intravenous immunoglobulin, Mycophenolate mofetil

*Correspondence:
Ayfer Arduç-Akçay
ayakcay@ku.edu.tr
[1]Department of Pediatric Neurology, Koç University School of Medicine, İstanbul, Türkiye
[2]Koç University School of Medicine, İstanbul, Türkiye
[3]Department of Ophthalmology, Koç University School of Medicine, Istanbul, Turkey

© The Author(s) 2026. **Open Access** This article is licensed under a Creative Commons Attribution-NonCommercial-NoDerivatives 4.0 International License, which permits any non-commercial use, sharing, distribution and reproduction in any medium or format, as long as you give appropriate credit to the original author(s) and the source, provide a link to the Creative Commons licence, and indicate if you modified the licensed material. You do not have permission under this licence to share adapted material derived from this article or parts of it. The images or other third party material in this article are included in the article's Creative Commons licence, unless indicated otherwise in a credit line to the material. If material is not included in the article's Creative Commons licence and your intended use is not permitted by statutory regulation or exceeds the permitted use, you will need to obtain permission directly from the copyright holder. To view a copy of this licence, visit http://creativecommons.org/licenses/by-nc-nd/4.0/.

Background

Neuroretinitis (NR) is an inflammatory condition characterized by unilateral visual loss resulting from optic disc edema, peripapillary serous detachment, and accumulation of lipid exudates in the macula [1–3]. While the etiology of NR can be infectious, inflammatory, autoimmune, or idiopathic [3, 4], it has also been associated with myelin oligodendrocyte glycoprotein antibody-associated disease (MOGAD) in adults [5, 6]. The overall prevalence of MOGAD is estimated at 1.3–2.5 per 100,000, with approximately one-third of cases occurring in children, further highlighting its rarity in this age group [7]. Although infectious NR can be observed in pediatric populations [8], its association with anti-myelin oligodendrocyte glycoprotein (anti-MOG) antibodies remains exceptionally rare.

In contrast to infectious NR, anti-MOG antibody-associated NR represents an immune-mediated demyelinating process that responds favorably to early immunotherapy. Particularly in children, the diagnosis can be easily overlooked due to its overlapping clinical findings with other forms of NR. Given that MOGAD may respond favorably to corticosteroids and intravenous immunoglobulin (IVIG), it is critical to recognize this uncommon presentation to prevent delayed or insufficient treatment [9].

To our knowledge, pediatric cases of MOGAD presenting as NR remain exceptionally rare, and detailed longitudinal observations are limited. In this report, we describe an 11-year-old girl with anti-MOG antibody-positive NR, highlighting the diagnostic challenges, clinical course, and remarkable response to immunotherapy in this rare pediatric manifestation of MOGAD.

Case presentation

An 11-year-old girl was admitted with acute visual loss in her right eye. One week before admission, she developed ocular pain associated with eye movement, followed by progressive painless blurring of vision that culminated in marked visual loss one day before the presentation. She had been previously healthy with no significant medical or ocular history. There were no remarkable findings in the patient's past medical or family history. Ophthalmologic examination revealed right-sided optic disc edema, splinter hemorrhages, and indistinct disc borders (Fig. 1a). Apart from these findings, physical examination was unremarkable. At the detailed ophthalmologic documentation, which was performed on day 3 of intravenous pulse corticosteroid therapy, best-corrected visual acuity was counting fingers at 30 cm in the right eye and 10/10 in the left eye. A marked relative afferent pupillary defect (RAPD, 3+) was present in the right eye. Slit-lamp examination demonstrated a quiet anterior segment bilaterally, with no anterior chamber inflammation and no vitreous cells. Fundus examination of the right eye confirmed pronounced optic disc edema with splinter hemorrhages and blurred disc margins, while the left fundus was normal. Fluorescein angiography was not performed due to the patient's young age and rapid clinical improvement following initiation of immunotherapy. The visual field testing could not be reliably performed in the right eye due to severe visual impairment; the left visual field was normal. Craniospinal magnetic resonance imaging (MRI) revealed marked thickening of the right optic nerve, accompanied by T2-FLAIR hyperintensity and heterogeneous contrast enhancement (Fig. 2). In addition, the optical coherence tomography (OCT) of the right eye revealed subretinal fluid and exudates extending from the optic disc to the fovea, accompanied by macular edema (Fig. 1b). Retinal nerve fiber layer analysis demonstrated diffuse thickening in the right eye. Based on the coexistence of optic disc edema and macular exudation with subretinal fluid extending to the fovea, NR was considered the most likely diagnosis.

The patient was treated with 30 mg/kg intravenous pulse prednisolone and empirical azithromycin and

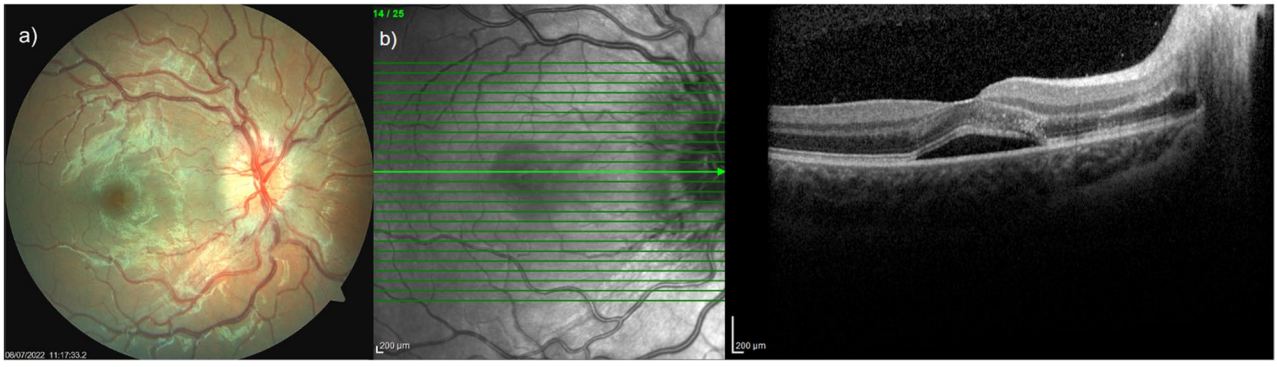

Fig. 1 Fundus photograph and macular OCT scan of the right eye on the third day of admission. Fundus imaging (**a**) shows marked optic disc edema with blurred margins, peripapillary hyperemia, and early macular exudation forming the initial components of a macular star. Corresponding spectral-domain OCT (**b**) demonstrates significant subretinal fluid with neurosensory retinal detachment and hyperreflective outer retinal deposits consistent with acute NR-related inflammation

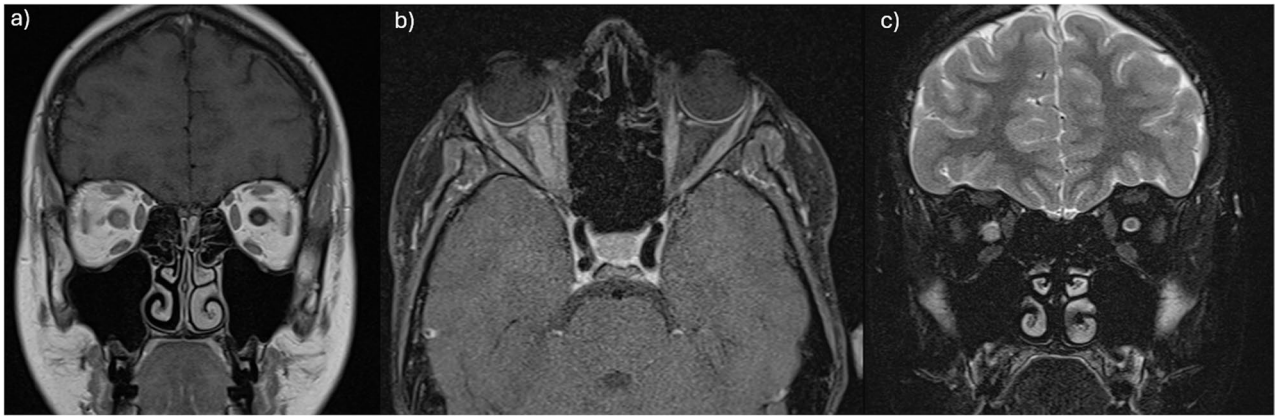

Fig. 2 MRI of the orbits and brain at presentation. Coronal post-gadolinium T1-weighted image (**a**) demonstrates contrast enhancement and thickening of the right optic nerve, consistent with active inflammatory involvement. Axial post-gadolinium fat-saturated T1-weighted image (**b**) shows intense enhancement of the right optic nerve, with clear asymmetry compared to the contralateral side. Coronal fat-saturated T2-weighted image (**c**) reveals hyperintensity and enlargement of the right optic nerve, supporting an inflammatory demyelinating process

doxycycline. Empirical antimicrobial therapy was initiated to cover common infectious causes of neuroretinitis but was discontinued as extensive microbiological workup remained negative and an immune-mediated etiology became evident. Cerebrospinal fluid analysis revealed a protein level of 28.5 mg/dL and a leukocyte count of fewer than 5 cells/μL; oligoclonal band analysis was negative. Serum aquaporin-4 antibodies were negative. Initial serum anti-MOG IgG testing was positive using immunofluorescence-based assay (IFA), while cerebrospinal fluid testing using a live cell-based assay (CBA) was negative. Although initial serum positivity was detected using an IFA, the diagnosis was supported by subsequent longitudinal confirmation of MOG-IgG seropositivity using live CBA during follow-up. Initial IFA positivity was interpreted with caution given its lower specificity; however, persistent seropositivity confirmed by live CBA during follow-up supported a true MOGAD phenotype. Antinuclear antibody (ANA) testing by indirect immunofluorescence on HEp-2 cells revealed a speckled pattern at a titer of 1:2560. Complement levels (C3 and C4) were within normal limits, and the erythrocyte sedimentation rate was 6 mm/h. Serologic tests for infectious etiologies, including Bartonella henselae, Borrelia burgdorferi, syphilis, and tuberculosis, were all negative. On the fourth day of pulse steroid therapy, since no meaningful improvement in visual acuity had been observed, IVIG was added to the treatment at a total dose of 2 g/kg.

On the 8th day of admission, after pulse steroid therapy and initiation of IVIG, visual acuity improved to 0.1 in the right eye. The anterior segment and vitreous remained quiet, and early macular star formation was noted along the papillomacular bundle, accompanied by increased vascular tortuosity and fullness, with persistent but regressing optic disc edema and blurred disc margins. Following IVIG administration, the patient also regained the ability to count fingers at a distance of 3 m. By the end of the second week, visual acuity further improved to 0.5, the relative afferent pupillary defect had resolved, and OCT demonstrated resolution of subfoveal fluid with improving macular architecture (Fig. 3a-b). Color vision testing could not be reliably assessed during the early follow-up period due to the patient's age and ongoing visual impairment. Formal visual field testing was not feasible at that stage. The patient was discharged on a tapered regimen of oral corticosteroid therapy.

At the third month of follow-up, visual acuity had further improved to 0.9, while fundus examination revealed optic disc pallor. OCT showed thinning of the right temporal rim, with an otherwise unremarkable macula (Fig. 4a-b). Repeat testing for anti-MOG antibodies continued to yield positive results. The patient's treatment continued with monthly IVIG infusions. However, due to a severe headache occurring as an adverse effect during IVIG administration, mycophenolate mofetil (MMF) was initiated in the third month. IVIG therapy was discontinued at month 6, while MMF treatment was continued for a total duration of 24 months. No clinical relapses were observed throughout the three-year follow-up period. At the final follow-up, visual acuity was 10/10 in both eyes. Color vision was normal, and formal visual field testing revealed no residual scotomas or visual field defects. Apart from residual optic disc pallor and mild temporal retinal nerve fiber layer thinning in the right eye, no long-term functional visual impairment was observed. Follow-up MRI showed residual thinning of the right optic nerve, consistent with prior inflammatory injury.

During follow-up, serum testing at the end of the one-year follow-up revealed positive results on IFA, while subsequent testing using live CBA also demonstrated borderline-positive MOG-IgG. Serial live CBA testing at the end of the second year remained persistently

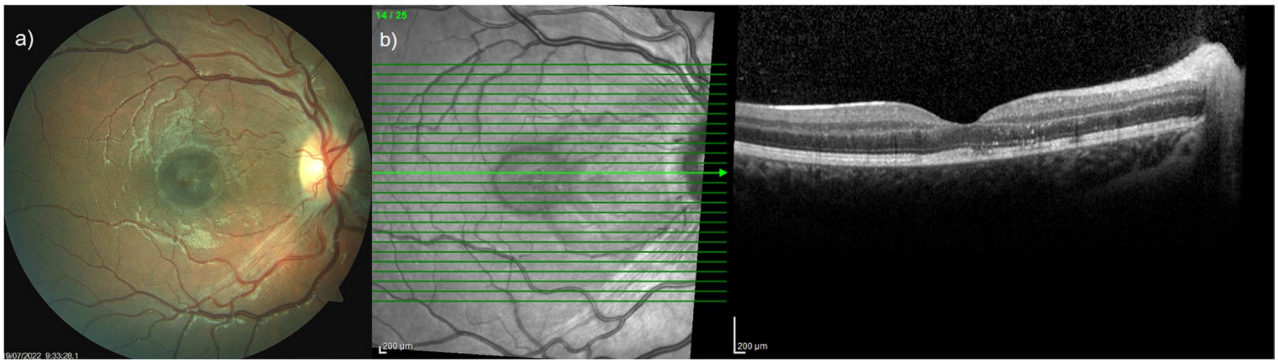

Fig. 3 Fundus photograph and macular OCT scan of the right eye at the end of the second week. Interval improvement is observed following initiation of high-dose corticosteroid and IVIG therapy. Fundus imaging (**a**) demonstrates decreased optic disc edema, reduced peripapillary inflammation, and partial resolution of macular exudates. Corresponding OCT (**b**) reveals near-complete resolution of subretinal fluid with restoration of the foveal contour. Mild residual outer retinal hyperreflective deposits persist, reflecting regressing inflammatory activity

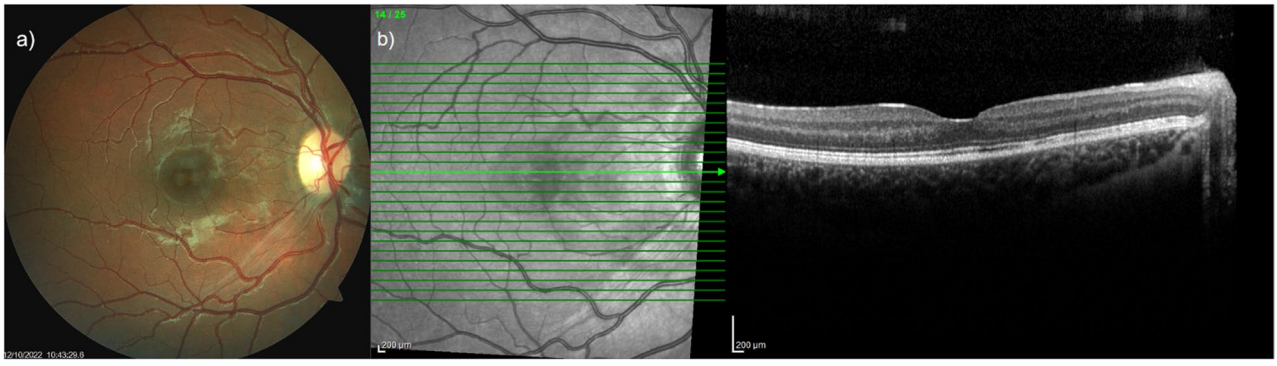

Fig. 4 Fundus photograph and macular OCT scan of the right eye at the end of third month. Fundus examination (**a**) shows complete resolution of optic disc edema and near-total disappearance of prior macular exudates. The optic disc demonstrates pallor, consistent with sequelae of resolved optic nerve inflammation. Corresponding OCT (**b**) confirms full anatomical recovery of the macula, with a restored foveal contour and no residual subretinal or intraretinal fluid. Only subtle outer retinal irregularities remain, reflecting prior inflammatory injury

borderline positive. Overall, the longitudinal serologic profile, with initial positivity and persistent low-level seropositivity confirmed by live CBA, was consistent with a MOGAD phenotype.

Discussion

This case illustrates a rare manifestation of MOGAD presenting as NR in a pediatric patient. While the ophthalmological manifestations of MOGAD, such as optic neuritis, are well recognized in children with acute vision loss [5], NR represents an exceptionally uncommon phenotype. The overlapping clinical and fundoscopic features with infectious or idiopathic NR may complicate diagnosis and delay appropriate management [10]. This case underscores the importance of considering MOGAD in children presenting macular star and optic disc edema, even in the absence of an infectious etiology.

MOGAD is an antibody-mediated demyelinating disorder of the central nervous system, in which immune reactions against myelin oligodendrocyte glycoprotein, expressed on the surface of oligodendrocytes, trigger complement activation, inflammatory cell recruitment, and secondary demyelination [11, 12]. In contrast to aquaporin-4-positive neuromyelitis optica spectrum disorder, MOGAD usually spares astrocytes and exhibits perivenous demyelination, with a predominance of myelin loss rather than necrosis [13]. The optic nerves, spinal cord, and brainstem are the most commonly affected regions [14]. Although these structures represent common targets of anti-MOG-antibody-related demyelination, ocular involvement may occasionally extend beyond the optic nerve [5]. The precise mechanism of retinal involvement in MOGAD remains unclear; however, inflammatory spillover into the peripapillary retina has been proposed as a potential pathway [15]. This process may increase vascular permeability at the optic disc, leading to lipid-rich exudation in the outer plexiform layer and the characteristic macular star observed in NR [5]. In this context, the exudation pattern in our patient likely reflects inflammation secondary to immune-mediated demyelination rather than a primary infectious or vascular cause.

MOGAD-related optic neuritis is not an infectious entity but an antibody-mediated autoimmune

demyelinating disorder, and infectious investigations are primarily pursued because NR has a broad infectious differential [1, 2, 14]. In pediatric patients, MOGAD can present with atypical neuro-ophthalmic phenotypes, and inflammatory involvement at the optic disc with secondary peripapillary retinal leakage has been proposed to account for subretinal fluid and lipid-rich macular exudation. Given the potential for relapses in MOGAD, follow-up should focus on recurrent clinical events, longitudinal MRI assessment, and structural/functional ophthalmic outcomes (RNFL/GCIPL thinning, visual fields), while MOG-IgG serostatus may be tracked as an adjunct rather than a standalone prognostic marker [9, 11, 15].

The diagnosis of NR in this patient was supported by the characteristic combination and temporal evolution of funduscopic and OCT findings rather than by optic neuritis alone. Although optic neuritis may be accompanied by optic disc edema and secondary macular changes, the presence of marked optic disc edema associated with lipid-rich macular exudation and subretinal fluid extending along the papillomacular bundle toward the fovea strongly favored NR [16]. While optic neuritis associated with MOGAD frequently presents with severe optic disc edema, it rarely produces the distinctive pattern of macular lipid exudation observed in this case. Taken together, the anatomical distribution of subretinal fluid, the evolution of macular exudates, and the funduscopic appearance over time are most consistent with a diagnosis of NR rather than optic neuritis with secondary macular involvement [16].

High-titer antinuclear antibody positivity was detected in this patient; however, no clinical, laboratory, or imaging findings suggestive of a systemic autoimmune disease emerged during the three-year follow-up. In pediatric patients, ANA positivity may occur as a nonspecific marker of immune activation and is frequently observed in the absence of overt systemic autoimmune disease [17, 18]. Isolated ANA positivity has been well documented in otherwise healthy children and in various non-rheumatologic inflammatory conditions [17, 18]. Moreover, ANA positivity has been reported in association with antibody-mediated demyelinating disorders, including MOGAD, without consistent clustering of systemic autoimmunity [19, 20]. Nevertheless, given the high titer observed in this case, careful long-term clinical surveillance for potential systemic autoimmune manifestations remains warranted.

To our knowledge, only one pediatric case of anti-MOG antibody-associated NR has been previously documented in the literature, underscoring the exceptional rarity of this condition [21]. However, the treatment details and long-term outcomes were not described. In contrast, the present case provides a more comprehensive longitudinal observation, demonstrating a favorable response to high-dose corticosteroids followed by IVIG and maintenance therapy with MMF. These findings are consistent with accumulating evidence that early and sustained immunotherapy can prevent relapses and promote visual recovery in MOGAD [22, 23]. Timely recognition and initiation of immunotherapy are critical in MOGAD-associated NR, as delayed treatment can result in irreversible optic nerve damage and recurrent visual deficits [1, 24].

In this case, prompt administration of high-dose corticosteroid allowed for partial recovery, and the addition of IVIG later led to rapid visual improvement. The favorable response confirms earlier findings that a combination of IVIG and corticosteroid therapy improves clinical recovery in MOGAD-related optic involvement [25]. The patient remained relapse-free during two years of MMF maintenance therapy, and immunotherapy was tapered after a low-positive anti-MOG antibody titer was detected at the end of this period. Notably, no relapses occurred following treatment discontinuation.

Long-term maintenance strategies in MOGAD vary widely, with azathioprine, MMF, rituximab, IVIG, and cyclophosphamide being the most frequently reported agents. There is no consensus regarding which patients require prolonged immunotherapy or which agent is preferable. Although maintenance therapy is often recommended for patients with relapsing disease, some studies have reported the use of extended oral corticosteroid tapers even after a first demyelinating event in MOG-IgG-positive individuals. The optimal duration of maintenance therapy, particularly after a first episode or in phenotypes traditionally associated with higher relapse risk, such as optic neuritis, remains uncertain [26].

Decisions regarding treatment discontinuation are similarly heterogeneous among clinicians and typically incorporate clinical remission duration, serologic status, relapse frequency and severity, and functional outcome. Importantly, anti-MOG antibody titers are imperfect predictors of relapse: persistent seropositivity may occur without clinical recurrence, and seronegative patients may still relapse, even if MOG-IgG later reappears or remains undetectable [27].

This report adds to the current understanding of MOGAD-associated NR in children, despite being limited to a single case, by providing comprehensive longitudinal follow-up and demonstrating full recovery with early and sustained immunotherapy.

Conclusion

This case highlights the expanding clinical spectrum of MOGAD and emphasizes that NR may represent a rare, vision-threatening manifestation of the disease. In pediatric patients presenting with optic disc edema and macular exudates, both infectious etiologies and

MOG-associated demyelination should be evaluated in parallel. Early recognition and timely initiation of appropriate immunotherapy can support full visual recovery and reduce the risk of recurrent demyelinating episodes.

Patient's perspective

The patient's caregiver stated that:

> *At first, we were very worried and confused because our child suddenly lost vision in one eye and we had no explanation. The doctors explained the condition and guided us through each step of the treatment. We were relieved to see her vision improving with treatment, and now she is back to her normal life.*

Abbreviations

anti-MOG	Anti-myelin oligodendrocyte glycoprotein
IVIG	Intravenous immunoglobulin
MRI	Magnetic resonance imaging
MMF	Mycophenolate mofetil
MOGAD	Myelin oligodendrocyte glycoprotein antibody-associated disease
NR	Neuroretinitis
OCT	Optical coherence tomography
IFA	Immunofluorescence-Based Assay
CBA	Cell-Based Assay
ANA	Antinuclear Antibody

Supplementary Information

The online version contains supplementary material available at https://doi.org/10.1186/s12883-026-04710-1.

Supplementary Material 1.

Acknowledgements

The authors thank the patient and her family for their cooperation.The authors used ChatGPT (OpenAI) for minor language refinement; all scientific interpretation and conclusions were made by the authors.

Authors' contributions

AAA performed the clinical evaluation as the attending pediatric neurologist. AYT contributed to the ophthalmological assessment and assisted in interpreting the ocular findings. YHB conducted the literature review and analyzed all clinical data, with additional clinical and scientific input from AAA. YHB and AAA prepared the figures and drafted the manuscript. AAA and AYT provided critical revision of the manuscript for important intellectual content. All authors read and approved the final manuscript.

Funding

This work received no specific grant from any funding agency in the public, commercial, or not-for-profit sectors.

Data availability

All data generated and analyzed during this case report are included in the published article. Additional information is available from the corresponding author upon reasonable request.

Declarations

Ethics approval and consent to participate

According to institutional and national regulations for single-patient case reports, formal ethics committee approval was not required. Written informed consent to participate was obtained from the patient's legal guardians.

Consent for publication

Written informed consent for publication of clinical details and images was obtained from the patient's legal guardians.

Competing interests

The authors declare no competing interests.

Received: 3 December 2025 / Accepted: 3 February 2026
Published online: 09 February 2026

References

1. Purvin V, Sundaram S, Kawasaki A. Neuroretinitis: review of the literature and new observations. J Neuroophthalmol. 2011;31(1):58–68. https://doi.org/10.1097/WNO.0b013e31820cf78a.
2. Abdelhakim A, Rasool N. Neuroretinitis: A review. Curr Opin Ophthalmol. 2018;29(6):514–9. https://doi.org/10.1097/ICU.0000000000000527.
3. Shi J, Danesh-Meyer HV, Bhatti MT. Neuroretinitis: A comprehensive review on aetiologies, clinical manifestations, and treatment options. Eye. 2025;39:238–50. https://doi.org/10.1038/s41433-024-03466-7.
4. Narayan SK, Kaliaperumal S, Srinivasan R. Neuroretinitis: A great mimicker. Ann Indian Acad Neurol. 2008;11(2):109–13. https://doi.org/10.4103/0972-2327.41879.
5. Vosoughi AR, Ling J, Tam KT, Blackwood J, Micieli JA. Ophthalmic manifestations of Myelin oligodendrocyte glycoprotein-IgG-associated disorder other than optic neuritis: A systematic review. Br J Ophthalmol. 2021;105(11):1591–8. https://doi.org/10.1136/bjophthalmol-2020-317267.
6. Moheb N, Chen JJ. The neuro-ophthalmological manifestations of NMOSD and MOGAD: A comprehensive review. NMOSD MOGAD:Eye. 2023;37:2391–8. https://doi.org/10.1038/s41433-023-02477-0.
7. Hor JY, Fujihara K. Epidemiology of Myelin oligodendrocyte glycoprotein antibody-associated disease: A review of prevalence and incidence worldwide. Front Neurol. 2023;14:1260358. https://doi.org/10.3389/fneur.2023.1260358.
8. Choi J, Bossuyt A, Chan NSW, Wu G. (2022). Paediatric retinal inflammatory disorders. In R. V. P. Chan, editor, Pediatric retinal diseases (Retina Atlas, pp. 1–20). Springer. https://doi.org/10.1007/978-981-19-1364-8_9
9. Nosadini M, Eyre M, Giacomini T, et al. Early immunotherapy and longer corticosteroid treatment are associated with lower risk of relapsing disease course in pediatric MOGAD. Neurology: Neuroimmunol Neuroinflammation. 2022;10(1):e200065. https://doi.org/10.1212/NXI.0000000000200065.
10. Parab SG, Sahdev SI. Spectrum of optic disc edema with macular star and neuroretinitis: A literature review. Delhi J Ophthalmol. 2025;35(2):85–91. https://doi.org/10.4103/DLJO.DLJO_97_24.
11. Sechi E, Cacciaguerra L, Chen JJ, et al. Myelin oligodendrocyte glycoprotein antibody-associated disease (MOGAD): A review of clinical and MRI features, diagnosis, and management. Front Neurol. 2022;13:885218. https://doi.org/10.3389/fneur.2022.885218.
12. Moseley CE, Virupakshaiah A, Forsthuber TG, Steinman L, Waubant E, Zamvil SS. MOG CNS autoimmunity and MOGAD. Neurol: Neuroimmunol Neuroinflamma. 2024;11(5):e200275. https://doi.org/10.1212/NXI.0000000000200275.
13. Takai Y, Misu T, Fujihara K, Aoki M. Pathology of Myelin oligodendrocyte glycoprotein antibody-associated disease: A comparison with multiple sclerosis and aquaporin-4 antibody-positive neuromyelitis Optica spectrum disorders. Front Neurol. 2023;14:1209749. https://doi.org/10.3389/fneur.2023.1209749.
14. Corbali O, Chitnis T. Pathophysiology of Myelin oligodendrocyte glycoprotein antibody disease. Front Neurol. 2023;14:1137998. https://doi.org/10.3389/fneur.2023.1137998.
15. Jeyakumar N, Lerch M, Dale RC, et al. MOG antibody-associated optic neuritis. Eye. 2024;38:2289–301. https://doi.org/10.1038/s41433-024-03108-y.
16. Bennett JL. Optic neuritis. Continuum (Minneap Minn). 2019;25(5):1236–64. https://doi.org/10.1212/CON.0000000000000768.
17. Ostrov BE. Reliability and reproducibility of antinuclear antibody testing in pediatric rheumatology practice. Front Med. 2023;9:1071115. https://doi.org/10.3389/fmed.2022.1071115.
18. Malleson PN, Mackinnon MJ, Sailer-Hoeck M, et al. Review for the generalist: the antinuclear antibody test in children - When to use it and what to do with a positive titer. Pediatr Rheumatol. 2010;8:27. https://doi.org/10.1186/1546-0096-8-27.
19. Molazadeh N, Bose G, Lotan I, Levy M. Autoimmune diseases and cancers overlapping with Myelin oligodendrocyte glycoprotein antibody-associated

disease (MOGAD): A systematic review. Multiple Scler J - Experimental Translational Clin. 2022;8(4). https://doi.org/10.1177/20552173221128170.
20. Porey C, Jaiswal BK. Systemic association of Myelin oligodendrocyte glycoprotein antibody disease: A systematic review of literature. Neurol Clin Neurosci. 2024;12:71–9. https://doi.org/10.1111/ncn3.12790.
21. Lee AR, El-Dairi MA. Anti-myelin oligodendrocyte glycoprotein optic neuritis or neuroretinitis? JAMA Ophthalmol. 2018;136(10):e182928. https://doi.org/10.1001/jamaophthalmol.2018.2928.
22. Havla J, Pakeerathan T, Schwake C, et al. Age-dependent favorable visual recovery despite significant retinal atrophy in pediatric MOGAD: how much retina do you really need to see well? J Neuroinflamm. 2021;18:121. https://doi.org/10.1186/s12974-021-02160-9.
23. Wang X, Kong L, Zhao Z, et al. Effectiveness and tolerability of different therapies in preventive treatment of MOG-IgG-associated disorder: A network meta-analysis. Front Immunol. 2022;13:953993. https://doi.org/10.3389/fimmu.2022.953993.
24. Fairbanks AM, Starr MR, Chen JJ, Bhatti MT. Treatment strategies for neuroretinitis: current options and emerging therapies. Curr Treat Options Neurol. 2019;21(8):36. https://doi.org/10.1007/s11940-019-0579-9.
25. Misu T, Matsumoto Y, Kaneko K, Takahashi T, Takai Y, Ono H, et al. Myelin oligodendrocyte glycoprotein antibody-associated disorders: an overview. Clin Experimental Neuroimmunol. 2024;15(1):6–15. https://doi.org/10.1111/cen3.12771.
26. da Costa BK, Banwell BL, Sato DK. Treatment of MOG-IgG-associated disease in paediatric patients: A systematic review. Multiple Scler Relat Disorders. 2021;56:103216. https://doi.org/10.1016/j.msard.2021.103216.
27. Whittam DH, Karthikeayan V, Gibbons E, Messina S, Molloy A, Hacohen Y, et al. Treatment of MOG antibody-associated disorders: results of an international survey. J Neurol. 2020;267(12):3565–77. https://doi.org/10.1007/s00415-020-10026-y.

Publisher's note

Springer Nature remains neutral with regard to jurisdictional claims in published maps and institutional affiliations.