Compressive Sonoelastography Findings of Esophageal Carcinoma

Mahmut Subasi[1], Afak Durur-Karakaya[2], Hilal Balta[3], Adem Karaman[4]

Cite this article as: *Subasi M, Durur-Karakaya A, Balta H, Karaman A. Compressive Sonoelastography Findings of Esophageal Carcinoma. Eurasian J Med 2019; 51(3): 267-9.*

ORCID IDs of the authors:
M.S.: 0000-0001-6299-3413
A.D.K.: 0000-0003-3604-6791
H.B. 0000-0003-3745-9694
A.K. 0000-0002-3091-0609

[1]Department of Thoracic Surgery, Erzurum Training and Research Hospital, Erzurum, Turkey; Department of Thoracic Surgery and Lung Transplantation, University of Health Sciences, Ankara City Hospital, Ankara, Turkey
[2]Department of Radiology, Erzurum Training and Research Hospital, Erzurum, Turkey; Department of Radiology, Koc University School of Medicine, Istanbul, Turkey
[3]Department of Pathology, Erzurum Training and Research Hospital, Erzurum, Turkey
[4]Department of Radiology, Ataturk University School of Medicine, Erzurum, Turkey

Received: November 14, 2018
Accepted: February 28, 2019

Correspondence to: Mahmut Subasi
E-mail: mahmutsubasi.dr@gmail.com

DOI 10.5152/eurasianjmed.2019.18406

Content of this journal is licensed under a Creative Commons Attribution 4.0 International License.

ABSTRACT

Objective: The aim of this study was to evaluate the compressive sonoelastography findings of primary esophageal carcinoma.

Materials and Methods: Esophageal specimens of the patients with a tumor staged earlier than T2, with no lymphadenopathy or distant metastasis, who underwent surgery, were evaluated by compressive sonoelastography under ex vivo conditions immediately following surgical excision. The compressive sonoelastography findings of primary esophageal carcinoma were recorded. Compressive sonoelastography measurements were made according to the esophageal muscle because of lack of fat tissue.

Results: The mean elasticity score was 3±1 (range, 1-4), and the mean strain ratio was 1±0.9 (range, 0.3-2.9).

Conclusion: Primary esophageal carcinoma is stiff based on the elasticity score, and it demonstrated a mean strain ratio similar to the esophageal muscle.

Keywords: Esophagus, carcinoma, sonoelastography

Introduction

Esophageal carcinoma is a very aggressive neoplasm with high mortality, and it is reported as the sixth leading cause of carcinoma death in 2012 [1]. Despite improvements in diagnostic and management strategies, the prognosis remains unfavorable [2]. A minority of patients (15%-30%) survive beyond 5 years postoperatively [3, 4]. The increasing incidence and poor prognosis of esophageal carcinoma poses a major global public health problem [5].

Several imaging modalities can be used in the diagnostic evaluation, including barium esophagogram, upper gastrointestinal endoscopy, computed tomography, and magnetic resonance imaging. However, to the best of our knowledge, there are no studies evaluating compressive sonoelastography findings of esophageal carcinoma.

Elastography is a strain imaging technique that assesses the tissue stiffness and creates a visual representation of the distribution of stiffness in the region of interest [6]. The tissue stiffness is estimated by measuring the strain of the tissue in response to mechanical stress, either by local compression or vibration.

In the present study, we aimed to evaluate the immediate postoperative compressive sonoelastography findings of esophageal carcinoma.

Materials and Methods

This research was designed as a prospective study and was approved by the local ethics committee. Informed consent was obtained from all patients.

Patients

Between January 2014 and June 2015, a total of 21 consecutive patients (12 males and nine females; mean age 67 years, interquartile range 47-82) were evaluated by upper gastrointestinal endoscopy and computed tomography, or positron emission tomography, before surgery. Ten patients with tumors at a stage earlier than T2 and with no lymphadenopathy or distant metas-

tasis underwent surgery. Patients with a higher carcinoma stage, lymphadenopathy, or distant metastasis managed by radiotherapy or chemotherapy were excluded from the study (n=11).

Compressive sonoelastography

Immediately following the surgical excision, each specimen (tumor containing esophagus tissue) was evaluated by compressive sonoelastography in the operating room. All specimens were evaluated by the same physician (ADK). Specimens were placed on a firm table to allow the evaluation of stiffness. The B-mode ultrasonography and freehand compressive sonoelastography were performed using a EUB-6500 (Hitachi Medical, Tokyo, Japan) scanner. The width of the largest lesion was recorded. Sonoelastograms were superimposed on B-mode images. All parameters obtained by sonoelastography were measured three times, and the mean value was calculated.

Table 1. Demographic, sonoelastographic, and prognostic features of the cases (n=10)

VARIABLE	Mean±SD or Frequency (percentage)	Interval
Age	64±11	47-82
Gender		
Male	4 (40%)	
Female	6 (60%)	
Location		
Distal esophagus	10 (100%)	
Pathology		
Squamous cell carcinoma	9 (90%)	
Adenocarcinoma	1 (10%)	
Diameter (cm)	4.2±1.6	2.5-7
Differentiation grade		
1	3 (30%)	
2	6 (60%)	
3	1 (10%)	
Invasion		
Submucosa	1 (10%)	
Muscularis propria	3 (30%)	
Adventitia	6 (60%)	
Lymph node	1.2±1.8	0–6
Vascular invasion		
No	6 (60%)	
Yes	4 (40%)	
Perineural invasion		
No	5 (50%)	
Yes	5 (50%)	
P53 mutation level	72±9	55-80
Ki67	76±14	50-90
Elasticity score	3±1	1-4
Strain ratio	1±0.9	0.3-2.9

We used compressive elastography to evaluate the elasticity score (ES) and strain ratio (SR) of the tumor. ES was measured based on the scale described by Itoh et al. [7]: (1) deformability of the entire tumor; (2) deformability of most of the tumor with small areas of peripheral stiffness; (3) peripheral deformability with a stiff center; (4) stiffness of the entire tumor; and (5) stiffness of the entire tumor and surrounding tissue. For each tumor, three measurements were taken from suitable sections, and the mean value was used (Figure 1).

The SR was calculated by dividing strain values measured from the regions of interest in the tumor (B) by those in the muscle tissue of esophagus (A) at a similar depth. Three measurements were taken in suitable regions, and the mean value was calculated (Figure 1).

Statistical Analysis

The statistical calculations were performed by "IBM SPSS Statistics for Windows, Version 21.0. Armonk, NY: IBM Corp." The continuous variables are expressed as mean±sd, categorical data is expressed as n (%).

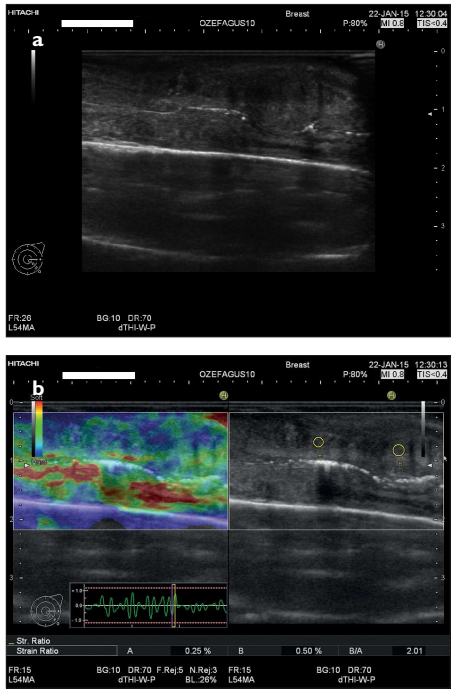

Figure 1. a, b. B-mode sonography (a) of an esophageal specimen showing a tumor on the side closest to the probe (arrow). The bright area represents air in the lumen. On the sonoelastography image (b), the tumor shows stiff areas (blue) compared to the muscle tissue at the same depth.

Pathologic examination

Histopathologic confirmation was done for all patents.

Results

Of 21 patients, 11 were excluded from the study for the reasons outlined above, leaving 10 patients (four males and six females; mean age 64±11 years, interquartile range 47-82) selected as suitable for surgical excision (Table 1). All of the tumors were located in the distal esophagus. The mean ES was 3±1 (range, 1-4), and the mean SR was 1±0.9 (range, 0.3–2.9).

The results of histopathological examination showed one adenocarcinoma and nine squamous cell carcinomas. The differentiation grade was two for six patients, one for three patients, and three for one patient. The level of invasion was the adventitia for six patients, muscularis propria for three patients, and submucosa for one patient. The number of positive lymph nodes was zero for four patients, one for four patients, two for one patient, and six for one patient. Vascular invasion was reported in four patients, and perineural invasion was observed in five patients. The mean p53 antibody level was 72% (±9%; range, 55%–80%), and mean Ki-67 was 76% (±14%; range, 50%–90%).

Discussion

In the present study, esophageal specimens with carcinoma were evaluated using compressive sonoelastography *ex vivo*. Tumors were stiff based on ES.

A few sonoelastography studies have previously been conducted on patients with esophageal carcinoma, and these were especially concerned with lymph nodes [8,9]. Knabe et al. reported that endosonographic elastography was able to improve the accuracy of the lymph node staging in patients with esophageal carcinoma [8]. Sazuka et al. examined the removed lymph nodes by putting each lymph node under the resected esophagus scanning each lymph node through the esophagus wall *ex vivo*, and they found that elastography was useful for diagnosing lymph node metastases in esophageal carcinoma [9]. In addition, a case report involving a patient with a tracheal tumor showed by elastography that the tumor had not invaded the esophagus [10]. However, to the best of our knowledge, there is no study in the English literature examining primary esophageal lesions by sonoelastography. In our study, esophageal carcinoma was evaluated by sonoelastography *ex vivo*, and ES and SR values were calculated.

The mean SR was 1±0.9 (range, 0.3–2.9) when compared to the esophageal muscle tissue. In

the breast, for example, comparisons are performed relative to the fat tissue, which is softer than the muscle tissue. However, esophagus specimens do not contain enough adipose tissue to allow such a comparison. The results may show that when the fat tissue is not used as a reference, the ES may be more reproducible in the determination of lesion stiffness than SR. In addition, when the muscle tissue is used for comparison, new cut-off values have to be estimated.

To prevent the specimen losing its tonus, sonoelastography was performed immediately after surgery, which allowed for tumors to be easily detected on grayscale images. The limitations of this study include a limited patient number and lack of benign esophageal tumors as a control group. Furthermore, sonoelastography is a relatively new tool, and compressive sonoelastography is relatively subjective. However, in this present study, investigations and measurements were performed three times by an experienced physician. On the other hand, there may be a population bias, because only patients who underwent surgery were enrolled. However, by this study we tried to present an innovative point of view by using sonoelastography and evaluate such a rare tumor. Although we examined postsurgical esophageal specimens, the use of sonoelastography by endoscopic ultrasonography may be considered and encouraged in the evaluation of esophageal tumors preoperatively.

In conclusion, primary esophagus carcinoma is a stiff lesion, and this feature has to be further researched in a larger series and compared to the benign pathologies.

Ethics Committee Approval: Ethics committee approval was received for this study from the Ethics Committee of Ataturk University School of Medicine (B.30.2.ATA.0.01.00/343).

Informed Consent: Informed consent was obtained from the patient.

Peer-review: Externally peer-reviewed.

Author Contributions: Concept – M.S., A.D.K., A.K., H.B.; Design - M.S., A.D.K., A.K., H.B.; Supervision - M.S., A.D.K., A.K., H.B.; Resource - M.S., A.D.K., A.K., H.B.; Materials - M.S., A.D.K., A.K., H.B.; Data Collection and/or Processing - M.S., A.D.K., A.K., H.B.; Analysis and/or Interpretation - M.S., A.D.K., A.K., H.B.; Literature Search - M.S., A.D.K., A.K., H.B.; Writing - M.S., A.D.K., A.K., H.B.; Critical Reviews - M.S., A.D.K., A.K., H.B.

Conflict of Interest: The authors declared no conflicts of interest.

Financial Disclosure: The authors declared that this study has received no financial support.

References

1. Torre LA, Bray F, Siegel RL, Ferlay J, Lortet-Tieulent J, Jemal A. Global cancer statistics, 2012. CA: a cancer journal for clinicians 2015; 65: 87-108. **[CrossRef]**
2. Li M, Fu C, Zhang W, Huang W, Wang Z, Zhou T, Lin H, Li B. Phase I study of concurrent selective lymph node late-course accelerated hyperfractionated radiotherapy and S-1 plus cisplatin for locally advanced oesophageal squamous cell carcinoma. Br J Radiol. 2016;89:20150476. **[CrossRef]**
3. Jemal A, Simard EP, Dorell C, et al. Annual Report to the Nation on the Status of Cancer, 1975-2009, featuring the burden and trends in human papillomavirus(HPV)-associated cancers and HPV vaccination coverage levels. Journal of the National Cancer Institute 2013; 105:175-201. **[CrossRef]**
4. Morita M, Yoshida R, Ikeda K, et al. Advances in esophageal cancer surgery in Japan: an analysis of 1000 consecutive patients treated at a single institute. Surgery 2008; 143: 499-508. **[CrossRef]**
5. Belkhiri A, El-Rifai W. Advances in targeted therapies and new promising targets in esophageal cancer. Oncotarget 2015; 6: 1348-58. **[CrossRef]**
6. Durur-Karakaya A, Durur-Subasi I, Akcay MN, Sipal S, Guvendi B. Sonoelastography findings for idiopathic granulomatous mastitis. Japanese journal of radiology 2015; 33: 33-8. **[CrossRef]**
7. Itoh A, Ueno E, Tohno E, et al. Breast disease: clinical application of US elastography for diagnosis. Radiology 2006; 239: 341-50. **[CrossRef]**
8. Knabe M, Gunter E, Ell C, Pech O. Can EUS elastography improve lymph node staging in esophageal cancer? Surgical endoscopy 2013; 27: 1196-202. **[CrossRef]**
9. Sazuka T, Akai T, Uesato M, et al. Assessment for diagnosis of lymph node metastasis in esophageal cancer using endoscopic ultrasound elastography. Esophagus : official journal of the Japan Esophageal Society 2016; 13: 254-63. **[CrossRef]**
10. Inage T, Nakajima T, Yoshida S, Yoshino I. Endobronchial elastography in the evaluation of esophageal invasion. The Journal of thoracic and cardiovascular surgery 2015; 149: 576-7. **[CrossRef]**