CASE REPORT – OPEN ACCESS

International Journal of Surgery Case Reports 5 (2014) 131–134

Contents lists available at ScienceDirect

International Journal of Surgery Case Reports

journal homepage: www.casereports.com

Port site and peritoneal metastases after robot-assisted radical prostatectomy

Ömer Acar[a,*], Tarık Esen[a,b], Sevil Bavbek[c], Önder Peker[d], Ahmet Musaoğlu[a]

[a] Department of Urology, VKF American Hospital, Nisantasi, 34365 Istanbul, Turkey
[b] School of Medicine, Koc University, Rumelifeneri Yolu, 34450 Istanbul, Turkey
[c] Department of Medical Oncology, VKF American Hospital, Nisantasi, 34365 Istanbul, Turkey
[d] Department of Pathology, VKF American Hospital, Nisantasi, 34365 Istanbul, Turkey

ARTICLE INFO

Article history:
Received 13 January 2014
Accepted 17 January 2014
Available online 24 January 2014

Keywords:
Port-site
Metastasis
Robot
Radical prostatectomy

ABSTRACT

INTRODUCTION: Port site metastasis after minimally invasive urologic surgery is a rare event despite the widespread utility of laparoscopic techniques in the management of urologic malignancies. Herein, we report a case of port site metastasis after robot-assisted radical prostatectomy.
PRESENTATION OF CASE: A currently 77-year-old male patient, who was diagnosed with cT2c, Gleason 7 (4+3) prostate adenocarcinoma in our clinic back in 2009, had undergone robot-assisted radical prostatectomy elsewhere. Histopathological examination revealed pT3a, Gleason 9 (4+5) disease. Lymph nodes were negative, however surgical margins were positive on the right side. PSA recurred after 9 months and maximal androgen blockade was initiated. Despite antiandrogenic manipulations, PSA reached 0.83 ng/ml, 33 months postoperatively. Concurrently, we noticed a palpable anterior abdominal mass which demonstrated metabolic hyperactivity on PET scanning. Percutaneous biopsy of the lesion confirmed the presence of metastatic adenocarcinoma. PSA did not normalize after the complete excision of the metastatic focus. Repeated PET scan revealed multiple implants on the peritoneal surfaces of various organs.
DISCUSSION: Port site and peritoneal metastasis of prostate cancer after robot-assisted radical prostatectomy has not been reported so far. This peculiar dissemination pattern is most probably the result of tumor biology and perioperative factors.
CONCLUSION: Although encountered extremely rarely, surgeons should be aware of the possibility of port site and/or peritoneal metastases after minimally invasive radical prostatectomy.
© 2014 The Authors. Published by Elsevier Ltd on behalf of Surgical Associates Ltd.
Open access under CC BY-NC-SA license.

1. Introduction

Port site metastasis is described as tumor implantation localized in the abdominal wall at the port of entry of the laparoscopic trocar and it is not associated with diffuse peritoneal carcinomatosis.[1] The first report of urologic tumor port seeding occurred after a diagnostic pelvic lymph node dissection for transitional cell carcinoma of the bladder.[2] However, to the best of our knowledge, port-site metastasis after robot-assisted radical prostatectomy has not been reported so far. Herein, we describe a patient who has developed port site recurrence as well as multiple peritoneal metastatic deposits after robot-assisted radical prostatectomy.

2. Presentation of case

A 66-year-old man presented with lower urinary tract symptoms in 2002. His baseline serum PSA value was 1.9 ng/ml and he had a mildly enlarged prostate (30 g) which did not harbor anything suspicious on digital rectal examination. He was offered medical treatment with alpha-adrenergic antagonists. He came back for routine follow-up visits every 6 months and his symptoms improved steadily. However, his serum PSA value showed a progressive increase and reached 5.6 ng/ml after 2 years. Transrectal prostate biopsy (TRUS-Bx) ruled out the presence of an underlying malignancy and he remained on alpha-blockers. Five years later, his PSA climbed up to 6.8 ng/ml at which time there was induration in the right lobe of the prostate. TRUS-Bx was repeated and this time a multifocal, high grade (Gleason 4+3=7) prostatic adenocarcinoma was detected. Bony tissue was free of metastasis on scintigraphic imaging. After a thorough discussion about the treatment options and considering his age at that moment (70 years old), we offered him radiotherapy combined with anti-androgens. However, he opted for surgical treatment and he underwent transperitoneal, robot-assisted laparoscopic radical prostatectomy in another country. According to the discharge summary of the

* Corresponding author. Tel.: +90 532 315 58 29; fax: +90 212 311 23 63.
E-mail address: omer_acar_@hotmail.com (Ö. Acar).

2210-2612 © 2014 The Authors. Published by Elsevier Ltd on behalf of Surgical Associates Ltd. Open access under CC BY-NC-SA license.
http://dx.doi.org/10.1016/j.ijscr.2014.01.010

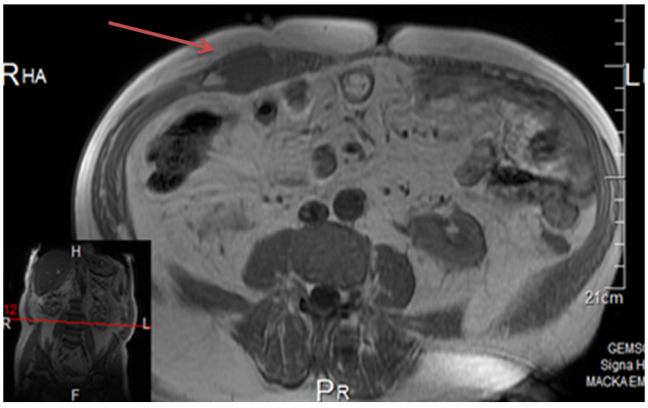

Fig. 1. Axial abdominal MR image demonstrating the presence of a mass (red arrow) located within the muscular layer of the anterior abdominal wall.

institution where the surgery was carried out, the perioperative and early postoperative period was uneventful. Histopathological examination revealed pT3a, Gleason 4 + 5 = 9 disease with a positive surgical margin on the right apex. Obturator and iliac lymph nodes were free of tumoral infiltration. The patient received no adjuvant treatment and PSA reached a nadir value (<0.02 ng/ml) 3 months postoperatively. However, after 9 months, PSA started to climb above 0.2 ng/ml. Metastatic work-up revealed negative findings and we recommended radiotherapy and hormonal treatment. However the patient refused radiation treatment and received only maximal androgen blockade with an LH–RH agonist and a non-steroidal antiandrogen. After a brief biochemical response, PSA started to rise again and it reached 0.67 ng/ml 21 months postoperatively, despite second-line hormonal manipulation. In the meantime, a small palpable mass situated superficially in the anterior abdominal wall came to attention. Abdominal MRI confirmed the presence of a round, homogenous anterior abdominal mass (Fig. 1) measuring 5 cm in its greatest dimension. This location was consistent with the right-hand port site. After documenting metabolic hyperactivity on FDG-PET scanning (Fig. 2), we sampled the lesion and histopathologic outcome was consistent with metastatic adenocarcinoma. Thirty-three months postoperatively, when the PSA was 0.83 ng/ml, we excised the lesion completely with clear margins (Fig. 3). The tumor was located within the anterior abdominal musculature, adjacent to the parietal peritoneal layer (Fig. 4). Skin and subcutaneous tissues did not contain any



Fig. 2. FDG-PET image demonstrating a hypermetabolic mass on the lateral border of the rectus muscle.



Fig. 3. Macroscopic view of the excised specimen. Intramuscularly located lesion (encircled in red) was removed together with the overlying skin and subcutaneous tissue.

malignant lesion. Seven months after this operation, during which he kept on receiving maximal androgen blockade, he developed low back pain and concurrently his serum PSA value rised to the level of 1.2 ng/ml. Repeated FDG-PET scan demonstrated the presence of multiple, milimetric, metastatic hypermetabolic implants along the peritoneal surface of various organs; namely right lobe and dome of liver, ascending colon, ureter and cecum (Fig. 5a and b). We then decided to add abiraterone acetate to the treatment regimen which showed its effect after 2 months with a mild PSA response (1.2–0.89 ng/ml). However, PSA bounced back up to 2.2 ng/ml after 6 months and eventually he was scheduled for chemotherapy.

3. Discussion

Shorter convalescence and decreased analgesic requirements, along with better cosmetic results are the main advantages of minimally invasive procedures. However, no oncologic benefit for a minimally invasive approach over open-surgical resection of cancer has been established.[3–5] For this reason, careful patient selection

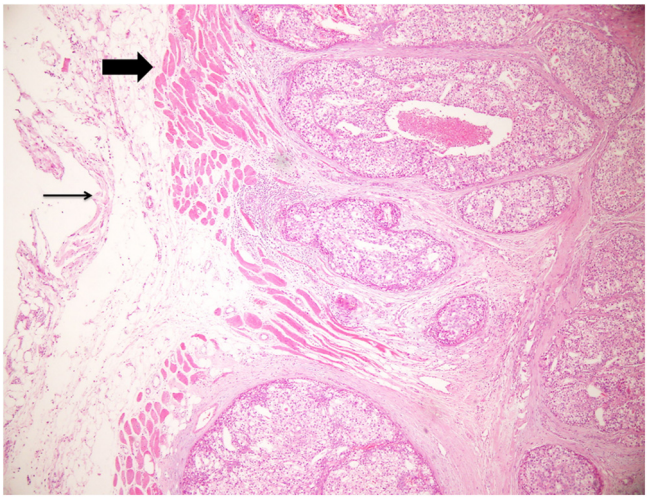

Fig. 4. High grade (Gleason 4 + 4 = 8) metastatic prostate adenocarcinoma that has infiltrated the striated muscle layer (thick arrow) of the abdominal wall. The deposit lies in close proximity to the parietal peritoneum (thin arrow). Skin and subcutaneous tissues were free of tumoral infiltration (not shown in this figure). Original magnification 40×, hematoxylin and eosin stain.

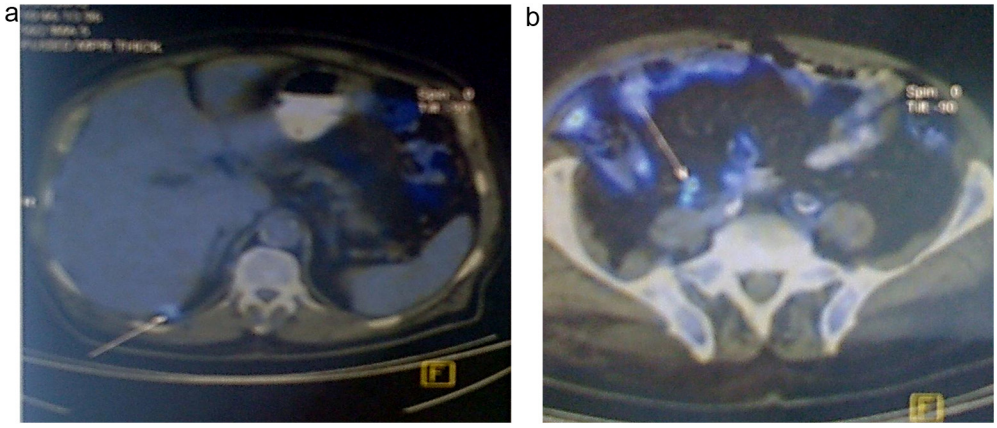

Fig. 5. a and b: FDG-PET scan revealing the presence of hypermetabolic foci located along various peritoneal surfaces (dome of the liver and right ureter in these figures)

is critical to keep tumor seeding to a minimum. Dobronte et al. reported the first case of port site metastasis after a laparoscopic procedure in 1978. Malignant ascites, that was originating from an ovarian cystadenoma, was the most probable source of spread in that particular patient.[6] The reported overall incidence of tumor seeding and port site metastasis in the literature ranges from 0.6% to 21%.[3,7] Micali et al. reviewed a total of 18,750 laparoscopic procedures, of which 10,912 were for cancer, and reported the incidence of port site seeding and peritoneal spread to be 0.09% (10 cases) and 0.03% (3 cases), respectively.[8] As a conclusion, they stated that tumor seeding after laparoscopic oncologic surgery is very rare and does not appear to be greater than that historically reported for open surgery.[8]

The first case of port site metastasis involving a urologic procedure was reported in 1994 after lymphadenectomy for transitional cell carcinoma of the bladder.[2] In a recent review by Castillo et al., which covered 17 studies reported in English literature, a total of 31 cases of port site metastasis or tumor seeding secondary to laparoscopic urologic procedures in the past 20 years have been identified.[9] The reported operation types in this review included nephrectomy, nephroureterectomy, cystectomy, pelvic lymph node dissection and retroperitoneal lymph node dissection but not radical prostatectomy.

Larrousse et al. reported a port site/subcutaneous recurrence in a patient with mucinous adenocarcinoma who had undergone laparoscopic radical prostatectomy and partial cystectomy extraperitoneally.[10] Savage et al. were the first to report a case of conventional prostate cancer with multiple port site metastases after laparoscopic radical prostatectomy. That patient also developed lymph node recurrence and widespread bony metastases, with a PSA of 1.15 ng/mL, likely representing poorly differentiated prostate cancer.[11]

Multiple theories have attempted to explain the probable mechanisms of port site metastases. Tumor related (high grade cancer), wound related (local immune response) and procedure related (morcellation, absence of bag retrieval) factors would appear to facilitate tumor seeding during laparoscopic surgery.[3,7,12–14] Port site metastasis after laparoscopic radical prostatectomy most likely results from a combination of these factors.

To the best of our knowledge, our case is the first example of a port site/peritoneal recurrence of prostate cancer after robot-assisted laparoscopic prostatectomy. Theoretically, it should be the result of the same multifactorial etiology that has been proposed about pure laparoscopic surgery. However, the peritoneal spread of metastatic lesions after the discovery of the anterior abdominal, intramuscular mass was noteworthy, especially in the absence of bony lesions. The locally advanced, high-grade disease and its unpredictable biologic behavior should be accepted as the primary underlying factor. We can only speculate about the other possibilities such as; the rapid cellular turnover of laparoscopic port sites and peritoneal incisions providing a fertile ground for cancerous cells,[15] the incisions that are too large and the trocars that are inserted in a nonorthogonal fashion allowing turbulent air flow and facilitating tumoral implantation[16] and lastly traumatic specimen extraction which can be the source of direct mechanical spread.[17]

4. Conclusion

Port site metastasis and tumor seeding after radical prostatectomy is exceedingly rare. We report the first case of port site recurrence after robot-assisted laparoscopic radical prostatectomy. The unusual recurrence site and peritoneal dissemination pattern in this case is most likely the result of tumoral characteristics and perioperative factors. Careful patient selection and strict adherence to basic oncologic surgical principles are of utmost importance in order to prevent such unusual scenarios.

Conflict of interest

We have no conflicts of interest to declare.

Funding

None.

Ethical approval

Written informed consent was obtained from the patient for publication of this case report and accompanying images. A copy of the written consent is available for review by the Editor-in-Chief of this journal on request.

Authors' contributions

Ömer Acar carried out the study concept and design, data collection, data interpretation, writing the paper, critical revision of the manuscript for scientific and factual content. Tarık Esen and Sevil Bavbek designed the study concept and design, writing the paper, critical revision of the manuscript for scientific and factual content, supervision. Data collection and interpretation were done by Önder Peker and Ahmet Musaoğlu.

References

1. Reymond MA, Schneider C, Kastl S, Hohenberger W, Köckerling F. The pathogenesis of port-site recurrences. *J Gastrointest Surg* 1998;**2**(5):406–14.
2. Stolla V, Rossi D, Bladou F, Rattier C, Ayuso D, Serment G. Subcutaneous metastasis after coelioscopic lymphadenectomy for vesical urothelial carcinoma. *Eur Urol* 1994;**26**(4):342–3.
3. Curet MJ. Port site metastases. *Am J Surg* 2004;**187**(6):705–12.
4. Stewart GD, Tolley DA. What are the oncological risks of minimal access surgery for the treatment of urinary tract cancer? *Eur Urol* 2004;**46**(4):415–20.
5. Rassweiler J, Tsivian A, Kumar AV, Lymberakis C, Schulze M, Seeman O, et al. Oncological safety of laparoscopic surgery for urological malignancy: experience with more than 1,000 operations. *J Urol* 2003;**169**(6):2072–5.
6. Dobronte Z, Wittman T, Karacsony G. Rapid development of malignant metastases in the abdominal wall after laparoscopy. *Endoscopy* 1978;**10**(2):127–30.
7. Ramirez PT, Wolf JK, Levenback C. Laparoscopic port-site metastases: etiology and prevention. *Gynecol Oncol* 2003;**91**(1):179–89.
8. Micali S, Celia A, Bove P, De Stefani S, Sighinolfi MC, Kavoussi LR, et al. Tumor seeding in urological laparoscopy: an international survey. *J Urol* 2004;**171**(6 Pt 1):2151–4.
9. Castillo OA, Vitagliano G. Port site metastasis and tumor seeding in oncologic laparoscopic urology. *Urology* 2008;**71**(3):372–8.
10. Larrousse C, Brasseur P, Sukkarieh F. Port-site metastasis following laparoscopic radical prostatectomy for mucinous adenocarcinoma of the prostate. *J Radiol* 2005;**86**(3):337–9.
11. Savage SJ, Wingo MS, Hooper HB, Smith MT, Keane TE. Pathologically confirmed port site metastasis after laparoscopic radical prostatectomy: case report and literature review. *Urology* 2007;**70**(6), 1222.e9–e11.
12. Lee BR, Tan BJ, Smith AD. Laparoscopic port site metastases: incidence, risk factors, and potential preventive measures. *Urology* 2005;**65**(4):639–44.
13. Fornara P. Port metastases: fact or fiction? *Urologe A* 2002;**41**(2):113–9.
14. Whelan RL, Lee SW. Review of investigations regarding the etiology of port site tumor recurrence. *J Laparoendosc Adv Surg Tech* 1999;**9**(1):1–16.
15. Hewett PJ, Texler ML, Anderson D, King G, Chatterton BE. In vivo real-time analysis of intraperitoneal radiolabeled tumor cell movement during laparoscopy. *Dis Colon Rectum* 1999;**42**(7):868–76.
16. Champault G, Taffinder N, Ziol M, Riskalla H, Catheline JM. Cells are present in the smoke created during laparoscopic surgery. *Br J Surg* 1997;**84**(7):993–5.
17. Tseng LNL, Berends FJ, Wittich PH, Bouvy ND, Marquet RL, Kazemier G, et al. Port-site metastases: impact of local tissue trauma and gas leakage. *Surg Endosc* 1998;**12**(12):1377–80.

Open Access
This article is published Open Access at sciencedirect.com. It is distributed under the IJSCR Supplemental terms and conditions, which permits unrestricted non commercial use, distribution, and reproduction in any medium, provided the original authors and source are credited.