ACTA ORTHOPAEDICA et TRAUMATOLOGICA TURCICA
www.aott.org.tr

Invited Review

A comprehensive review of scapulothoracic abnormal motion (STAM): evaluation, classification, and treatment strategies

Cemil Cihad Gedik[1], İlker Eren[1], Mehmet Demirhan[1], Bassem Elhassan[2]

[1]Department of Orthopaedics and Traumatology, Koç University School of Medicine, Istanbul, Türkiye
[2]Department of Orthopaedic Surgery, Harvard Medical School, Massachusetts General Hospital Boston Shoulder Institute, Boston, USA

ARTICLE INFO

Article history:
Submitted August 16, 2024
Accepted September 2, 2024
Publication Date September 18, 2024

Keywords:
Scapula
Scapular winging
Scapulothoracic abnormal motion
Shoulder pain

ORCID iDs of the authors:
C.C.G. 0000-0002-7431-063X;
İ.E. 0000-0003-2965-7690;
M.D. 0000-0001-8411-7596;
B.E. 0000-0002-6694-0535.

ABSTRACT

The term "dyskinesia" has often been used interchangeably with "winging," leading to ambiguity in the literature. To address this, the broader term "scapulothoracic abnormal motion (STAM)" was introduced to describe any abnormal position or movement of the scapula on the chest, resulting in pain and dysfunction. Scapulothoracic abnormal motion has a wide range of causes, including musculoskeletal imbalances such as pectoralis minor hyperactivity, neurological impairments such as long thoracic nerve palsy, and genetic conditions like facioscapulohumeral muscular dystrophy (FSHD). This review aims to identify the different causes and classifications of STAM and to propose a detailed treatment algorithm specifically designed to manage these conditions effectively.

Introduction

The use of "dyskinesia" has often been confused with or interchangeably used for "winging," leading to ambiguity in the literature. To address the issues with current nomenclature, the broader term scapulothoracic abnormal motion (STAM) was introduced. This term simply indicates abnormalities in the position and motion of the scapula on the chest, resulting in pain and dysfunction.[1]

The shoulder complex comprises 3 joints—the acromioclavicular joint, glenohumeral joint, and sternoclavicular joint—along with the scapulothoracic articulation.[2,3] This articulation, although not a true joint, plays a critical role in shoulder movement and stability. Six periscapular muscles, namely the serratus anterior, trapezius, levator scapulae, rhomboid major, rhomboid minor, and pectoralis minor, are instrumental in controlling the motion and stability of the scapula against the thoracic wall.[4,5]

Among these muscles, the serratus anterior and trapezius are particularly vital. They are the primary large muscles responsible for stabilizing, supporting, and facilitating smooth motion of the scapula on the chest wall, thereby ensuring efficient shoulder function.[4]

When patients exhibit symptoms of STAM, particularly when accompanied by a restricted range of motion (ROM), pain, and instability, it is imperative to conduct a thorough investigation. This meticulous approach ensures that the underlying causes are accurately identified and appropriately addressed, fostering more targeted and effective treatment strategies.

In summary, STAM's etiological spectrum is vast, ranging from dynamic musculoskeletal imbalances, such as pectoralis minor hyperactivity, to neurological impairments including nerve paralysis. Additionally, genetic muscular dystrophies can have a significant role, with hereditary muscular dystrophies like facioscapulohumeral muscular dystrophy (FSHD) often manifesting as STAM.[6-10] This diversity in underlying causes underscores the complexity of diagnosing and managing STAM, necessitating a comprehensive understanding of its multifaceted nature. Each etiology brings its unique pathophysiology, influencing the scapulothoracic articulation and the interaction between the scapula and the thoracic wall. Therefore, recognizing the wide array of factors that can lead to STAM is crucial for developing effective, individualized treatment plans that address the specific needs of each patient.

The aim of this review is to delineate the various etiologies and subtypes of STAM and to introduce a comprehensive treatment algorithm tailored to address these conditions effectively.

Anatomy and biomechanics of the scapula and periscapular muscles

The periscapular muscles, including the serratus anterior, rhomboid major, rhomboid minor, and levator scapulae, play a crucial role in the complex biomechanics of shoulder movement. These muscles collaborate to stabilize the scapula against the thoracic wall, providing a solid foundation for the efficient operation of the glenohumeral joint. As the scapula is the "house for the rotator cuff," the scapula's stability is essential

Corresponding author:
Cemil Cihad Gedik
ccihadgedik@gmail.com or
cgedik@ku.edu.tr

Content of this journal is licensed under a Creative Commons Attribution-NonCommercial 4.0 International License.

Cite this article as: *Gedik CC, Eren İ, Demirhan M, Elhassan B. A comprehensive review of scapulothoracic abnormal motion (stam): evaluation, classification, and treatment strategies. Acta Orthop Traumatol Turc., 2024;58(4):187-195.*

DOI: 10.5152/j.aott.2024.24066

for proper shoulder function and range of motion.[4] The serratus anterior is particularly vital for scapular protraction and upward rotation, facilitating overhead arm elevation and ensuring optimal alignment of the glenohumeral joint for maximal upper limb movement.[11,12]This muscle's functionality is critical in activities requiring overhead reach, where its weakness or dysfunction can result in scapular winging, adversely affecting shoulder biomechanics.

Conversely, the rhomboids and levator scapulae primarily mediate scapular retraction and elevation, respectively, acting as antagonists to the serratus anterior.[4,13] These muscles' coordinated action is crucial for maintaining scapular stability and alignment, particularly during arm adduction and activities involving pulling or lifting. The synergistic function of these periscapular muscles ensures the scapula's movements are finely tuned to the demands of upper limb activities, facilitating efficient force transmission from the trunk to the arm. This complex interplay is vital for the preservation of shoulder stability and function.

Evaluation

Scapulothoracic abnormal motion often results in posterior shoulder discomfort that might extend along the arm and up to the cervical region. The onset of symptoms, which may include spontaneous pain or discomfort triggered by activities, as well as sensations such as clicking or popping during arm movements, necessitates a thorough patient history to determine potential causes. Critical elements of this history include the patient's dominant hand, employment activities, any past injuries, medical history, and previous interventions on the shoulder, neck, thorax, or breasts. Moreover, any type of functional STAM can be associated with functional thoracic outlet syndrome, especially STAM type 1, which may result in subjective paresthesia in the upper extremity as well as pain in the periscapular area.[14]

Diagnosing STAM predominantly relies on a comprehensive musculoskeletal examination. During this evaluation, it's essential to observe the positioning and movement of both scapulae with the patient's back fully exposed, assessing for any signs of STAM, asymmetry, or muscle atrophy as the arms are lifted. To further evaluate the strength and mechanical functionality of the scapulae, specific maneuvers such as the shoulder flexion resistance test, which assesses movement of the scapula during forward arm elevation, and the scapular compression test, where manual pressure on the scapula may alleviate pain and enhance mobility, are employed. (Figure 1) These tests are instrumental in confirming the presence of STAM and guiding subsequent management strategies.

Electromyography (EMG) is an important tool to assess muscle activation abnormalities around the scapulothoracic (ST) joint that lead to STAM, especially in the presence of muscle paralysis.[15] Surface EMG, is a noninvasive technique that helps delineate the activation pattern of muscles surrounding the ST articulation, typically in the sequence of the upper trapezius, anterior deltoid, pectoralis major, serratus anterior, and then the rotator cuff. Notably, muscles like the pectoralis minor, rhomboid major, and latissimus dorsi exhibit minimal or no activity under normal conditions.[16]

In patients exhibiting STAM due to hyperactivity of the pectoralis minor and abnormal activation patterns of surrounding muscles, clinical manifestations often mimic serratus anterior dysfunction. This scenario is characterized by hyperactivity of the pectoralis minor and upper trapezius, along with the hypoactivity of the serratus anterior.

Distinguishing between pectoralis minor hyperactivity and serratus anterior paralysis through physical examination involves several specific tests: the shoulder flexion resistance test (SFRT) at 30°, the wall push-up test, and shoulder protraction against resistance. While the SFRT at 30° and wall push-up tests may indicate pectoralis minor hyperactivity, they are not exclusive to serratus dysfunction. It is important to note that when the wall push-up test is used to evaluate scapular motion, it only assesses 2 planes of scapular movement and does not account for the entire dynamic function of the scapular musculature.[17,18] As a result, it may not be a reliable tool for evaluating STAM, and its use is not recommended. Surface EMG assessments reveal that pectoralis minor activation does not significantly alter the scapula's position on the chest wall when the shoulder is flexed beyond 90°. Conducting the SFRT at varying angles—30°, 60°, and 100°—facilitates differentiation between these conditions. (Figure 2) Specifically, a negative SFRT at 100° suggests a functional serratus anterior, exhibiting a 100% negative predictive value for serratus anterior paralysis. Conversely, a positive SFRT across 30°, 60°, and 100° angles strongly indicates serratus anterior paralysis.[17]

This optimized approach, incorporating both physical examination techniques and surface EMG, enables a more accurate diagnosis of the underlying causes of STAM. It provides a clearer understanding of whether symptoms stem from pectoralis minor hyperactivity, serratus anterior dysfunction, or a combination of muscle activation abnormalities and guides the targeted treatment strategies to address specific muscular dysfunctions contributing to STAM.

Classification of scapulothoracic abnormal motion

Previous classifications of scapular dyskinesis, such as the system developed by Kibler et al,[7,19] primarily focus on diagnostic categorization rather than guiding treatment strategies. Kibler's classification delineates scapular motion abnormalities into 3 types, each corresponding to a specific plane of motion relative to the thorax. Type I is marked by the prominence of the inferior medial border, indicating abnormal rotation around a transverse axis. Type II involves the prominence of the entire medial border, indicative of abnormal rotation around a vertical axis. Type III features superior translation of the entire scapula, with prominence at the superior medial border.[19] Although this classification effectively identifies different patterns of scapular dyskinesis by observing the scapula at rest and during controlled arm movements, it serves more as a tool for understanding the biomechanical implications of these patterns rather than providing direct therapeutic directions. The categorization aids in recognizing the specific type of dyskinesis, but it does not extend to detailed treatment protocols or interventions that target the underlying causes or specific rehabilitation needs dictated by each type.

HIGHLIGHTS

- The diagnosis and management of scapulothoracic abnormal motion (STAM) require detailed physical examinations and, when necessary, diagnostic imaging and neurophysiological studies to accurately identify and address the specific underlying pathology.
- The scapula plays a crucial role in shoulder stability and movement, with its pathologies directly impacting the shoulder's range of motion and overall quality of life, emphasizing the need for targeted treatment strategies for STAM.
- Due to the diverse etiologies of STAM, including musculoskeletal imbalances and neurological conditions, treatment must be meticulously tailored to the specific pathology, aiming for both symptomatic relief and corrective intervention at the etiological level.

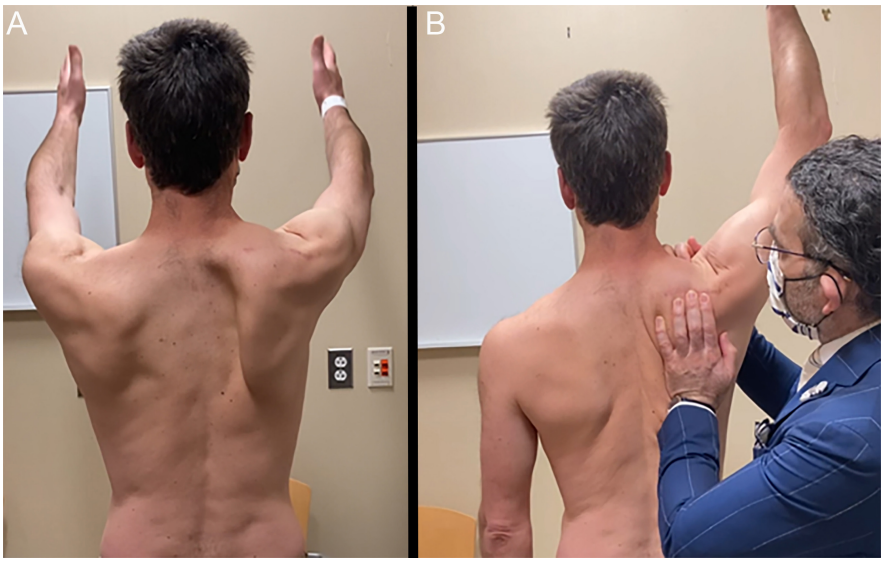

Figure 1. (A) STAM with elevation. (B) Scapular compression test and improvement in shoulder flexion.

STAM 1

STAM 1 is characterized by hyperactivity of the pectoralis minor, resulting in minimal STAM, anterior tilt of the scapula, and tenderness at the pectoralis minor insertion, alongside hyperactivity of the upper trapezius. Patients may experience some degree of motion limitation. It is important to keep in mind that this type may be associated with thoracic outlet syndrome.[14] In cases refractory to conservative treatment, a simple pectoralis minor release can be used for treatment.

STAM 2A

STAM 2A involves more pronounced STAM, hyperactivity of the pectoralis minor, and underactivation of the serratus anterior. The condition can be easily corrected with the Horwitz maneuver, leading to a good range of motion and indicating optimal periscapular muscle function, thus resembling serratus anterior dysfunction.

STAM 2B

STAM 2B is also characterized by hyperactivity of the pectoralis minor and underactivation of the serratus anterior. However, correction is more challenging but achievable, increasing shoulder flexion. The Horwitz maneuver is harder to perform, and the condition mirrors a lesser degree of serratus anterior dysfunction.

For both STAM 2A and 2B, the SFRT is negative at 100°. Diagnosis of the condition is based on clinical observations such as excessive anterior tilt of the affected shoulder and increased tenderness at the pectoralis minor insertion compared to the unaffected side. Two specific tests—shoulder flexion against resistance and shoulder protraction against resistance—are utilized to assess serratus anterior function, with the absence of scapula winging during these tests indicating functional, though hypoactive, serratus anterior muscle. Patients displaying STAM during shoulder flexion, linked to excessive anterior scapular tilt, find resolution in their instability through simple scapular stabilization on the chest wall, confirming the relationship between posterior instability and STAM.

STAM 3: serratus anterior paralysis

Serratus anterior paralysis is a well-known disorder associated with long thoracic nerve palsy (Figure 3). It can arise from various etiologies including direct compression or injury. In evaluating patients with serratus anterior (SA) paralysis (Figure 3), the wall push-up test is not recommended. Instead, 2 alternative tests are utilized. The first is shoulder flexion against resistance (SFRT), whichis positive at 30°, 60°, and 100° in patients with SA paralysis. This test has proven reliable for identifying SA muscle weakness in patients with chronic injuries (Figure 4). The second test involves resisted shoulder protraction, where the examiner applies resistance to the anterior shoulder as the patient attempts to protract.[17] This test helps identify varying degrees of scapular winging, indicating SA muscle weakness, with an emphasis on ensuring the patient performs true scapular protraction rather than internal rotation. While these tests can clearly identify normal function or complete paralysis, grading SA function in cases of partial dysfunction remains challenging.

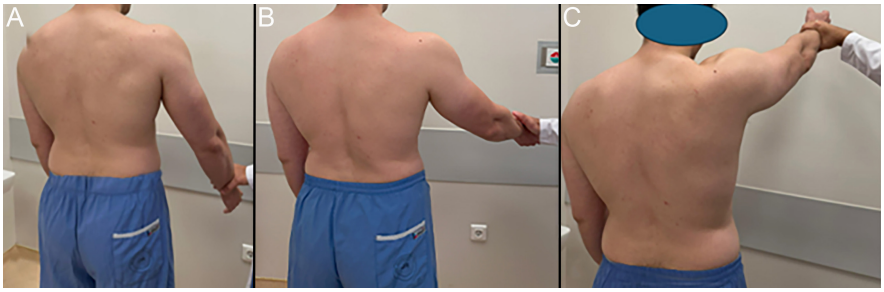

Figure 2. Negative SFRT at 30° (A), 60° (B), and 100°(C).

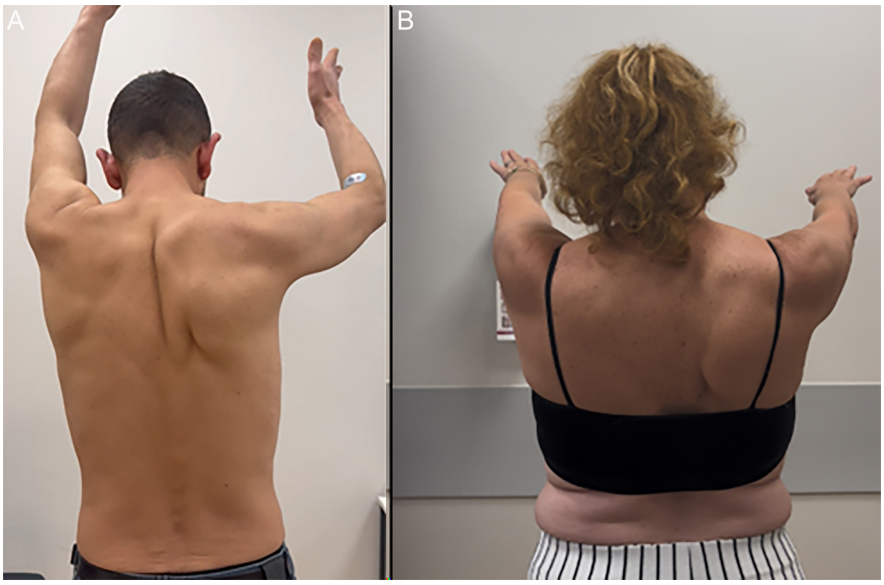

Figure 3. Patients with serratus anterior paralysis–long thoracic nerve palsy (STAM 3).

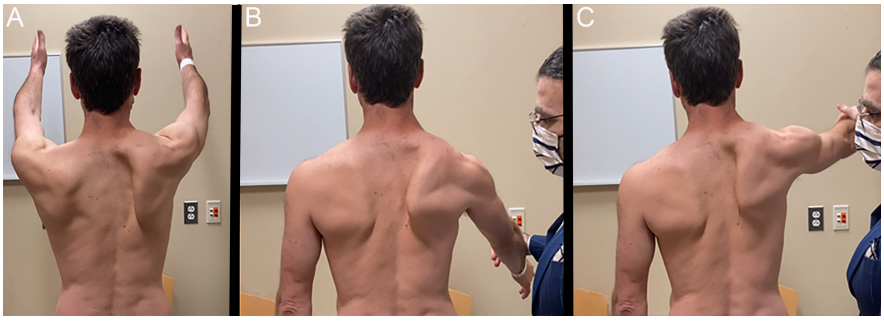

Figure 4. (A) STAM 3, serratus anterior dysfunction, (B and C) Positive shoulder flexion resistance test at 60° and 100°.

STAM 4: trapezius paralysis

STAM 4 is identified by paralysis of the trapezius muscle, a condition that profoundly impacts the scapulothoracic motion, often mimicking "winging" of the scapula. In this scenario, the SFRT is negative in lower degrees as other muscles compensate to maintain scapular stability, whereas in higher degrees of flexion SFRT is positive reflecting increased scapular instability due to trapezius dysfunction.

Trapezius paralysis leads to a distinct presentation in physical examinations due to the muscle's crucial role in scapular stabilization and movement. The trapezius, spanning the neck, shoulders, and upper back, assists in elevating, retracting, and rotating the scapula, facilitating arm raising above the head. When the trapezius is paralyzed, the scapula cannot maintain its alignment against the thoracic wall, especially during arm elevation, leading to the appearance of winging.[20]

Moreover, patients with trapezius paralysis may exhibit a drooping shoulder on the affected side (Figure 5), limited ability to lift the arm above shoulder level, and discomfort during shoulder movements due to the imbalance in muscular forces acting on the scapula.[21] Physical examination might also reveal atrophy of the trapezius muscle in chronic cases.

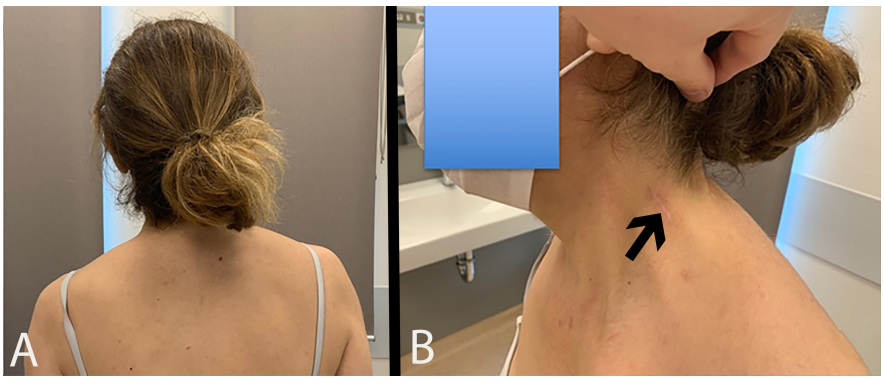

Figure 5. (A) Trapezius paralysis and atrophy. (B) Previous cervical lymph node biopsy incision, complicated by spinal accessory nerve palsy, resulting in paralysis.

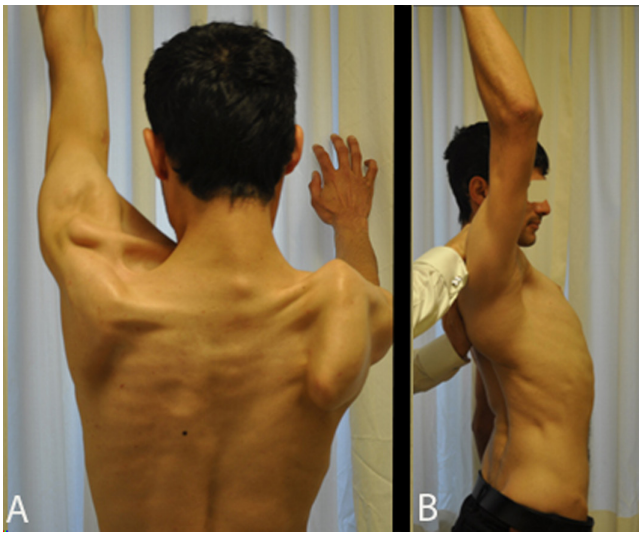

Figure 6. A: STAM 5, B: improvement in forward flexion with scapular assistance test (Horwitz maneuver).

Addressing trapezius paralysis and its consequent STAM involves a comprehensive approach, focusing on restoring scapular stability and function through physical therapy aimed at strengthening the remaining periscapular muscles. However, in some cases, surgical interventions might be necessary to reposition or stabilize the scapula to alleviate symptoms and improve shoulder function.

STAM 5

STAM 5 is characterized by a combination of trapezius and serratus anterior atrophy, a condition commonly observed in patients with FSHD. This dual dysfunction results in a more pronounced STAM due to the critical roles both muscles play in stabilizing and facilitating movement of the scapula along the thoracic wall. Despite the significant impairment, the scapular position in STAM 5 can often still be manually corrected or "reduced" using the Horwitz maneuver, indicating a potential for surgical intervention[22] (Figure 6).

Patients with FSHD experiencing STAM 5 exhibit a hallmark clinical presentation, including severe scapular winging and difficulty in achieving a full range of shoulder elevation. Physical examination reveals a marked imbalance in scapulothoracic dynamics, with visible winging evident even in neutral positions and further exacerbated by any attempt to move the arm away from the body.[23,24]

A previously described staging system identifies shoulder dysfunction and scapular winging in FSHD patients. This system categorizes patients into 6 stages based on arm elevation, deltoid muscle function, and scapular winging. Stage 0 represents optimal muscle function with no functional limitations, where surgery offers no benefit. Stage 1 patients show minimal periscapular involvement with mild winging; surgery may improve posture but not function. Stage 2 includes those with moderate winging and preserved deltoid function, where the benefits of surgery are uncertain and usually limited. Stage 3 individuals have severe winging and atrophic periscapular muscles, affecting daily activities; they benefit most from surgical intervention for both functional gains and cosmetic reasons. Stage 4 describes patients with similar muscle atrophy but partial deltoid functionality, where surgery can still offer cosmetic improvements and some functional benefits. Finally, Stage 5 patients have almost no functional deltoid muscles, making surgical intervention unlikely to improve outcomes. This detailed staging allows for tailored treatment plans, enhancing patient care by aligning surgical decisions with the specific functional impairments of FSHD. This system was published as a staging system, but the progression of the disease from one form to another stage has never been reported and therefore it may be more accurately considered a classification system.[25]

Management of STAM 5, especially in the context of FSHD, requires a multifaceted approach. Physical therapy focuses on optimizing the function of the remaining periscapular muscles, improving posture, and enhancing the range of motion through tailored exercises. In certain cases, surgical interventions such as scapulothoracic fusion or scapular tethering may be considered to stabilize the scapula and reduce winging, thereby improving shoulder function and quality of life. (Figure 7)

STAM 6

Trapezius and serratus anterior paralysis can lead to a condition where the scapula is "locked" in a position characterized by a dynamic anterior tilt that is nonreducible under normal conditions. This specific posture results from the inability of these crucial muscles to function in synchrony and move the scapula correctly, leading to abnormal scapular mechanics and motion. Intriguingly, while the abnormal positioning appears fixed and nonreducible in a conscious state, reduction is possible under anesthesia, indicating that muscle spasms or tension may contribute to the scapula's locked position.

This type is predominantly observed in young females and may present with spastic movements of the scapula. The spastic motion could be due to compensatory mechanisms or the involvement of other periscapular muscles trying to stabilize the scapula in the absence of the trapezius and serratus anterior function.

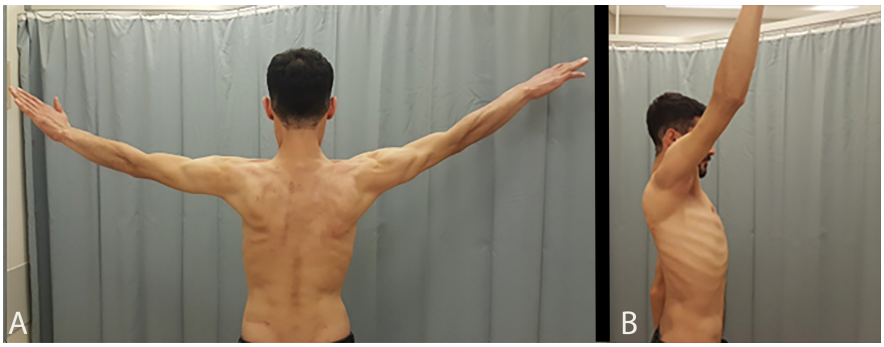

Figure 7. Bilateral scapulothoracic arthrodesis results in significant improvement in shoulder forward flexion.

When managing this condition, it is essential to address the intricate interaction between muscle paralysis, spasticity, and the mechanical immobilization of the scapula. Initial treatment approaches often focus on nonsurgical interventions, such as physical therapy, to address muscle spasms and improve periscapular muscle strength and coordination. Techniques such as neuromuscular re-education, stretching exercises, and targeted strengthening may help mitigate the spastic motion and improve scapular mobility.

In cases where conservative management does not lead to significant improvement, surgical interventions may be explored.

STAM 7A and STAM 7B

STAM 7A and STAM 7B describe variations of a condition known as "dancing scapula," characterized by involuntary, erratic movements of the scapula. This phenomenon significantly impacts the stability and function of the shoulder, leading to challenges in performing daily activities and specific movements.

STAM 7A

STAM 7A, or "Dancing Scapula with Activity," occurs in response to voluntary shoulder or arm movements. This variant suggests that the abnormal scapular motion is triggered or exacerbated by specific actions, indicating a reactive pattern linked to muscular activation or shoulder girdle movement. Management strategies often focus on identifying and modifying the activities that provoke the erratic movements, alongside therapeutic interventions aimed at strengthening the periscapular muscles to improve scapular stability and control.

STAM 7B

STAM 7B, or "Spontaneous Dancing Scapula," involves involuntary scapular movements that occur without any apparent trigger or voluntary shoulder activity. This form of dancing scapula points to a more complex underlying neuromuscular issue, where the scapula moves unpredictably and without the influence of targeted shoulder motion. Treatment for STAM 7B may require a more in-depth neurological evaluation to understand the root causes of the spontaneous movements, potentially including pharmacological intervention to manage neuromuscular excitability and physical therapy focused on maximizing shoulder stability.

Both STAM 7A and STAM 7B necessitate an extensive approach for diagnosis and management, involving detailed clinical evaluation and possibly imaging or neurophysiological studies to elucidate the underlying mechanisms driving the dancing scapula phenomenon. A tailored, multidisciplinary treatment plan, possibly incorporating physical therapy, medication, and, in some cases, surgical intervention, can help mitigate the symptoms and improve the quality of life for individuals affected by this condition.

In the context of STAM 7A and STAM 7B, or "dancing scapula," where patients experience involuntary, erratic scapular movements, it is essential to consider the role of neuropsychiatric conditions that could potentially contribute to or exacerbate these symptoms. The unusual and involuntary nature of the movements might not only be a manifestation of a physical neuromuscular disorder but could also be linked to underlying psychiatric issues. Therefore, a thorough psychiatric evaluation is critical to determine if psychological factors are influencing these physical symptoms.

Treatment

STAM 1 treatment

STAM 1 treatment for patients diagnosed with STAM 1 or grade 1 pectoralis minor syndrome primarily focuses on addressing pectoralis minor hyperactivity. Initial management includes a comprehensive rehabilitation program designed to target and alleviate the symptoms. If these conservative measures do not yield satisfactory results, the next step involves the administration of botulinum toxin (Botox) injections directly into the pectoralis minor muscle to temporarily reduce its overactivity. Should both rehabilitation efforts and Botox injections fail to provide relief, the final treatment option available is arthroscopic pectoralis minor release surgery. This approach is reserved for those who do not respond to nonsurgical interventions, categorizing them within the specific treatment pathway for Grade 1 of pectoralis minor syndrome.[26]

Technique

The surgical procedure involves the use of a preoperative interscalene brachial plexus block and general anesthesia, with the patient positioned in the beach-chair setup. Standard arthroscopic tools are employed, including a 30° arthroscope, an arthroscopic shaver, and a radiofrequency ablation device. The operation begins with diagnostic arthroscopy and bursoscopy, followed by the treatment of any associated pathologies as needed.

The main focus of the surgery is the release of the pectoralis minor (Pm) tendon. This is achieved by first removing the anterior bursal tissues between the anterior deltoid and the subscapularis to expose the lateral coracoid and the conjoint tendon. With the shoulder in flexion to relax the anterior deltoid, an anterior portal is created for direct visualization of the coracoid process and nearby structures. Through a medial working portal, created under direct vision, a blunt instrument is used to delineate the superior and inferior margins of the Pm tendon carefully, avoiding nearby neurovascular structures and any abnormal adhesions.

Subsequently, a radiofrequency ablation device is employed to detach the Pm tendon subperiosteally from the coracoid, with the device's thermal end oriented superiorly and laterally. The procedure concludes with the complete release of the Pm tendon and its medial retraction, all of which are verified through direct visualization.

STAM 2A and 2B treatment

STAM 2A and 2B treatment is "sexy-pexy," pectoralis minor release, and scapulopexy (Figure 8). Scapulopexy is used primarily to allow time for muscle rehabilitation rather than to provide stable fixation.

Surgery is considered for those who do not respond to at least 6 months of conservative treatments, including physical therapy, conservative measures, Botox injections, and electrical stimulation of the serratus anterior, and who continue to exhibit abnormal scapular motion and persistent pain. The surgical procedure involves an initial arthroscopic pectoralis minor release followed by an open scapulopexy.[9]

Surgical Technique

The patient is positioned in lateral decubitus, and an arthroscopic release of the pectoralis minor is performed through portals in the subacromial space. This step includes resecting the anterior bursa

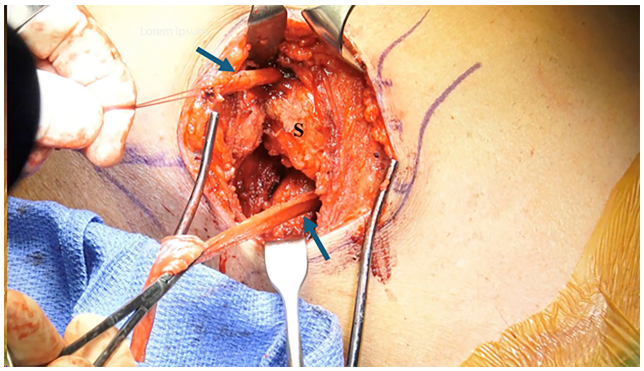

Figure 8. Scapulopexy. Arrows; allograft, S; scapula.

and opening the clavipectoral fascia to access and release the pectoralis minor insertion on the coracoid, ensuring no damage to the conjoint tendon.

Following the arthroscopic part, attention shifts to the posterior scapula for the open scapulopexy. A U-shaped incision near the inferior scapular tip exposes the underlying serratus anterior muscle, which is assessed for normality using a nerve stimulator. A hole is then created at the distal scapular tip for the tendon allograft, with care taken to avoid weakening the scapula structurally. The seventh rib is prepared, ensuring to pause ventilation to avoid pleural injury, and a loop of suture is passed around it. The tendon allograft, prepared from the tibialis posterior and treated with vancomycin, is then passed through this loop and secured around the seventh rib and through the scapula. The procedure concludes by suturing the overlapped ends of the tendon allograft and ensuring scapular stability against the chest wall, with no winging observed when the patient moves the arm. The surgical site is checked for air leaks to confirm no pleural injury. Post-operatively, the shoulder is immobilized in a sling for 6 weeks, followed by a gradual rehabilitation program starting with active assisted ROM exercises and aqua therapy, with no stretching or strengthening allowed until 12 weeks post-surgery.

STAM 3 treatment

Patients presenting with shoulder pain, scapular winging, and limited shoulder ROM, particularly in flexion and abduction, and showing no improvement after at least 1 year of conservative management, including those with documented long thoracic nerve injury without signs of reinnervation on EMG, are considered candidates for surgery. The surgical technique involves the transfer of the sternal head of the pectoralis major (PM) muscle, along with its bone insertion, to the inferior pole of the scapula to address these symptoms.[27]

Technique

The procedure starts with the patient positioned semi-laterally, and the surgical site prepared from the upper neck to the upper abdomen. An incision is made near the PM's humeral insertion to expose the muscle, followed by the detachment of the PM's sternal head using an electric saw and its preparation for transfer. The operation proceeds with an incision near the distal scapula to prepare it for receiving the transferred muscle. The PM is then maneuvered into position and attached to the scapula, with special care taken to avoid neurovascular bundle damage. The transfer is reinforced with sutures, and the clavicular head of the PM is reattached to its original location on the humerus. The surgery aims to restore shoulder function and alleviate symptoms associated with scapular winging and SA muscle dysfunction.

STAM 4 treatment

Triple tendon transfer for patients suffering from chronic trapezius paralysis who have not responded to conservative treatments or are unsuitable candidates for nerve repair or reconstruction. The surgery is indicated for individuals with persistent symptoms lasting more than 3 years.[28]

Technique

The procedure begins with the patient in a semilateral position to ensure the affected shoulder is optimally exposed while protecting pressure points around the lateral malleolus, fibular head, greater trochanter, and iliac crest. An inverted L incision is made to expose the trapezius muscle, which typically presents with atrophy and lack of contractile response. Key to this procedure is the use of a dynamic arm holder to facilitate mobilization and traction, allowing for precise dissection and exposure of the levator scapulae, rhomboid minor, and rhomboid major muscles. The surgical technique involves detaching the lower, middle, and upper parts of the trapezius and using an oscillating saw to carefully remove the bony insertions of the trapezius followed by their medial retraction to protect the dorsal scapular nerve. Subsequent steps include debridement of the scapular spine to encourage bleeding and the placement of transosseous sutures for muscle reattachment. Before muscle transfers, temporary patient paralysis is induced to simplify the repositioning of the levator scapulae, rhomboid minor, and major to their new insertion points on the scapula. Throughout the transfer process, continuous visualization of the dorsal scapular nerve ensures its protection. The technique culminates with the reattachment of the trapezius muscle to its original site, emphasizing the restoration of shoulder functionality and the meticulous preservation of nerve integrity.

STAM 5[22,29]

The surgical technique for scapulothoracic arthrodesis in patients with FSHD aims to stabilize the scapula against the thoracic wall, thereby improving shoulder function. This procedure is particularly beneficial for FSHD patients who experience significant scapular winging and shoulder girdle weakness.

Technique

The surgical technique for scapulothoracic arthrodesis in patients with FSHD is designed to address the impaired shoulder function caused by the disease. The procedure begins with the patient being placed under general anesthesia and positioned prone on the operating table, with their arms abducted and externally rotated to allow for optimal access to the scapulothoracic area. A longitudinal incision is made between the medial border of the scapula and the spinous processes of the vertebrae. Dissection is carried out through the nonfunctional trapezius and rhomboid muscles, exposing the posterior rib cage. The exposure of 4 to 5 ribs, from the second to the seventh depending on the positioning of the scapula, is achieved using a rib stripper in a subperiosteal plane, ensuring the protection of the intercostal neurovascular bundle and underlying pleura. Then, decortication of the dorsal aspects of the ribs and the medial border of the scapula to create bleeding bone surfaces, which is essential for the fusion process, is performed. Reconstruction plates, acting as washers, can be positioned on the dorsal surface of the scapula, and multifilament wires or FiberTape (Arthrex, Naples FL, USA) Cerclages are meticulously passed

through pre-drilled holes in the scapula around the ribs. Fresh-frozen femoral head allograft can also be used as grafting material between the ribs and scapula, enhancing bone healing and fusion. Autograft from iliac crests can also be harvested and used for the same purpose. The cerclage wires or cables are then tightened to secure the scapula against the ribs, and additional graft material is packed around the fusion site. The muscle layers and skin are then closed over a suction drain to ensure proper hemostasis and prevent postoperative fluid accumulation. An erector spinae plane block catheter may be used to decrease postoperative pain.[30] Postoperatively, patients are immobilized in a shoulder sling with a posterior strap to prevent rotation, with immobilization lasting up to 12 weeks. This period is crucial for allowing the fusion to heal properly. After this period, physical therapy is initiated to regain range of motion and strength, with a careful approach to avoid disrupting the fusion site.

STAM 6, 7A and 7B

For patients classified under STAM grades 6, 7A, and 7B, traditional management strategies like the "sexypexy" technique may not yield satisfactory outcomes. In these advanced cases, conservative approaches, including physical therapy focused on strengthening and range of motion exercises, have often been exhausted without significant improvement in patient condition. As a more advanced and innovative intervention, a surgical approach involving right-to-left scapula tethering is recommended. If all other treatments fail, scapulothoracic arthrodesis may be used as a last resort. While scapulothoracic fusion can stabilize the scapula, it does not always guarantee improvement in functional problems.

This method entails the use of an Achilles tendon allograft to create a durable and functional connection between the scapulae, aiming to stabilize scapular motion and alleviate symptoms associated with these specific STAM subtypes. Written informed consent was obtained from the patients who agreed to take part in the study.

Conclusion

The diagnosis and management of STAM rely heavily on comprehensive clinical evaluations, including detailed physical examinations and, when necessary, diagnostic imaging and neurophysiological studies (Figure 9). These assessments help delineate the type of STAM, guiding targeted treatment plans. STAM encompasses a wide spectrum of disorders, each with its unique pathology, ranging from musculoskeletal imbalances like pectoralis minor hyperactivity to neurological conditions such as nerve paralysis and genetic disorders like FSHD. This diversity underlines the complex interactions between the scapula and the thoracic wall, emphasizing the importance of a thorough understanding of the scapula's role in shoulder stability and movement.

As the house of the rotator cuff, the scapula's role extends beyond mere motion. It is integral in maintaining the overall biomechanical integrity of the shoulder complex. The stability and functionality of the scapula directly influence the shoulder's range of motion and the ability to perform daily activities, highlighting why its pathologies significantly impact the quality of life. Given the varied etiology of STAM, treatment strategies should be meticulously tailored to address the specific underlying pathology. This approach ensures that therapeutic interventions are not only symptomatic but also corrective at the etiological level, potentially offering more sustained relief and functional recovery. There is a need for more research and studies to further understand the complex nature of STAM and to develop innovative treatment strategies that can provide better outcomes for patients.

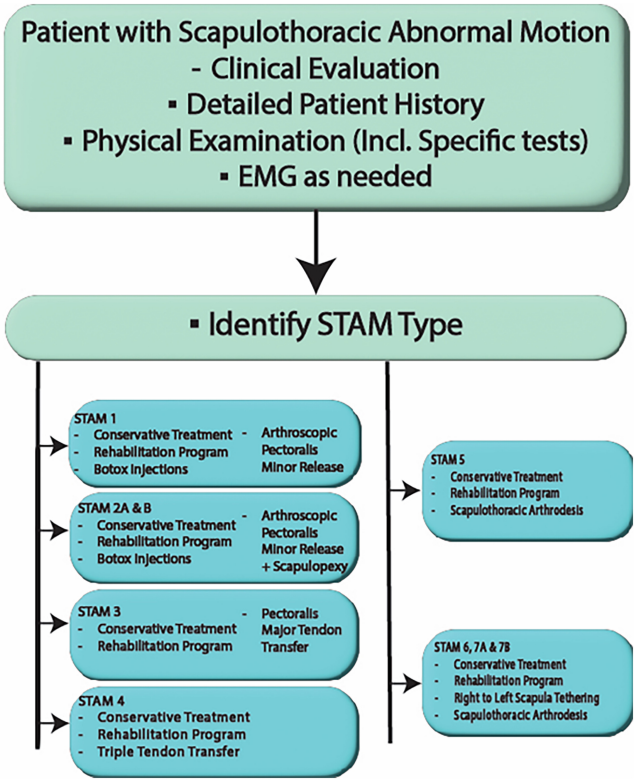

Figure 9. Treatment flowchart for STAM subtypes. STAM; scapulothoracic abnormal motion.

Data Availability Statement: The data that support the findings of this study are available on request from the corresponding author.

Informed Consent: Written informed consent was obtained from the patients who agreed to take part in the study.

Peer-review: Externally peer-reviewed.

Author Contributions: Concept – İ.E., M.D., B.E.; Design – C.C.G., İ.E., M.D., B.E.; Supervision – M.D., B.E.; Resources – İ.E., M.D., B.E.; Materials – C.C.G., İ.E., M.D., B.E.; Data Collection and/or Processing – C.C.G., İ.E.; Analysis and/or Interpretation – C.C.G., İ.E.; Literature Search – C.C.G., İ.E.; Writing – C.C.G., İ.E., B.E.; Critical Review – M.D., B.E.

Declaration of Interests: İlker Eren is an Associate Editor and Cemil Cihad Gedik is a Technical Editor at Acta Orthopaedica et Traumatologica Turcica, however, their involvement in the peer-review process was solely as authors. The other authors have no conflict of interest to declare.

Funding: The authors declared that this study has received no financial support.

References

1. Zhang D, Garg R, Elhassan B. 3d-printing assisted clavicle osteotomy for scapulothoracic abnormal motion: a case report. *JSES Rev Rep Tech*. 2023;3(4):553-556. [CrossRef]
2. Halder AM, Itoi E, An K-N. Anatomy and biomechanics of the shoulder. *Orthopedic Clinics of North Am*. 2000;31(2):159-176. [CrossRef]
3. Kent BE. Functional anatomy of the shoulder complex: a review. *Phys Ther*. 1971;51(8):867-888. [CrossRef]
4. Crowe MM, Elhassan BT. Scapular and shoulder girdle muscular anatomy: its role in periscapular tendon transfers. *J Hand Surg Am*. 2016;41(2):306-315. [CrossRef]
5. Kibler WB, Sciascia A. Periscapular muscles. *Norm Pathol Anat Shoulder*. 2015:275-278.
6. Burkhart SS, Morgan CD, Kibler WB. The disabled throwing shoulder: spectrum of pathology part iii: the sick scapula, scapular dyskinesis, the kinetic chain, and rehabilitation. *Arthroscopy*. 2003;19(6):641-661. [CrossRef]

7. Kibler WB, McMullen J. Scapular dyskinesis and its relation to shoulder pain. *J Am Acad Orthop Surg*. 2003;11(2):142-151. [CrossRef]
8. Lee S, Savin DD, Shah NR, Bronsnick D, Goldberg B. Scapular winging: evaluation and treatment: AAOS exhibit selection. *J Bone Joint Surg Am*. 2015;97(20):1708-1716. [CrossRef]
9. Elhassan BT, Dang KH, Huynh TM, Harstad C, Best MJ. Outcome of arthroscopic pectoralis minor release and scapulopexy for the management of scapulothoracic abnormal motion. *J Shoulder Elbow Surg*. 2022;31(6):1208-1214. [CrossRef]
10. Paraskevopoulos E, Papandreou M, Gliatis J. Reliability of assessment methods for scapular dyskinesis in asymptomatic subjects: a systematic review. *Acta Orthop Traumatol Turc*. 2020;54(5):546-556. [CrossRef]
11. Ekstrom RA, Bifulco KM, Lopau CJ, Andersen CF, Gough JR. Comparing the function of the upper and lower parts of the serratus anterior muscle using surface electromyography. *J Orthop Sports Phys Ther*. 2004;34(5):235-243. [CrossRef]
12. Ekstrom RA, Soderberg GL, Donatelli RA. Normalization procedures using maximum voluntary isometric contractions for the serratus anterior and trapezius muscles during surface emg analysis. *J Electromyogr Kinesiol*. 2005;15(4):418-428. [CrossRef]
13. Kao JT, Pink M, Jobe FW, Perry J. Electromyographic analysis of the scapular muscles during a golf swing. *Am J Sports Med*. 1995;23(1):19-23. [CrossRef]
14. Ahmed AS, Graf AR, Karzon AL, et al. Pectoralis minor syndrome – review of pathoanatomy, diagnosis, and management of the primary cause of neurogenic thoracic outlet syndrome. *JSES Rev Rep Tech*. 2022;2(4):469-488. [CrossRef]
15. Parel I, Jaspers E, DE Baets L, Amoresano A, Cutti AG. Motion analysis of the shoulder in adults: kinematics and electromyography for the clinical practice. *Eur J Phys Rehabil Med*. 2016;52(4):575-582.
16. Castelein B, Cagnie B, Parlevliet T, Cools A. Serratus anterior or pectoralis minor: which muscle has the upper hand during protraction exercises? *Man Ther*. 2016;22:158-164. [CrossRef]
17. Lohre R, Elhassan B. Serratus anterior dysfunction examination: wall push-up or shoulder flexion resistance test? *JSES Int*. 2022;6(5):859-866. [CrossRef]
18. Lunden JB, Braman JP, LaPrade RF, Ludewig PM. Shoulder kinematics during the wall push-up plus exercise. *J Shoulder Elbow Surg*. 2010;19(2):216-223. [CrossRef]
19. Kibler WB, Sciascia A. Current concepts: scapular dyskinesis. *Br J Sports Med*. 2010;44(5):300-305. [CrossRef]
20. Paine R, Voight ML. The role of the scapula. *Int J Sports Phys Ther*. 2013;8(5):617-629. [CrossRef]
21. Seror P, Stojkovic T, Lefevre-Colau MM, Lenglet T. Diagnosis of unilateral trapezius muscle palsy: 54 cases. *Muscle Nerve*. 2017;56(2):215-223. [CrossRef]
22. Eren İ, Gedik CC, Kılıç U, Abay B, Birsel O, Demirhan M. Management of scapular dysfunction in facioscapulohumeral muscular dystrophy: the biomechanics of winging, arthrodesis indications, techniques and outcomes. *EFORT Open Rev*. 2022;7(11):734-746. [CrossRef]
23. Statland J, Tawil R. Facioscapulohumeral muscular dystrophy. Continuum (minneap minn). 22 (6, muscle and neuromuscular junction disorders). 2016;1916-1931.
24. Khadilkar SV, Chaudhari CR, Soni G, Bhutada A. Is pushing the wall, the best known method for scapular winging, really the best? a comparative analysis of various methods in neuromuscular disorders. *J Neurol Sci*. 2015;351(1-2):179-183. [CrossRef]
25. Eren İ, Birsel O, Öztop Çakmak ÖÖ, et al. A novel shoulder disability staging system for scapulothoracic arthrodesis in patients with facioscapulohumeral dystrophy. *Orthop Traumatol Surg Res*. 2020;106(4):701-707. [CrossRef]
26. Haeni D, Martinez-Catalan N, Esper RN, Wagner ER, El Hassan BT, Sanchez-Sotelo J. Arthroscopic release of the pectoralis minor tendon from the coracoid for pectoralis minor syndrome. *J Exp Orthop*. 2022;9(1):57. [CrossRef]
27. Elhassan BT, Wagner ER. Outcome of transfer of the sternal head of the pectoralis major with its bone insertion to the scapula to manage scapular winging. *J Shoulder Elbow Surg*. 2015;24(5):733-740. [CrossRef]
28. Elhassan BT, Wagner ER. Outcome of triple-tendon transfer, an Eden-Lange variant, to reconstruct trapezius paralysis. *J Shoulder Elbow Surg*. 2015;24(8):1307-1313. [CrossRef]
29. Eren İ, Erşen A, Birsel O, Atalar AC, Oflazer P, Demirhan M. Functional outcomes and complications following scapulothoracic arthrodesis in patients with facioscapulohumeral dystrophy. *JBJS Am*. 2020;102(3):237-244. [CrossRef]
30. Gürkan Y, Sincer Y, Manici M, Gedik CC, Eren İ, Demirhan M. Erector spinae plane block for scapulothoracic arthrodesis for facioscapulohumeral dystrophy patients: a case series. *A&A Pract*. 2023;17(2):e01662. [CrossRef]